

SHORT COMMUNICATION

PATHOLOGICAL FINDINGS IN LAYING HENS WHICH DIED DUE TO HEAT STRESS: CASE REPORT

Pavol MAKOVICKÝ¹, Peter BOLGÁČ², Mária MAKOVICKÁ^{3,4}, Kristína JAKIČ³, Peter MAKOVICKÝ^{3*}

¹Department of Biology, Faculty of Education, J. Selye University, Komárno, Slovak Republic

²Department of Pathology, Veterinary and Food Institute, Bratislava, Slovak Republic

³Biomedical Research Center, Slovak Academy of Sciences, Cancer Research Institute, Bratislava, Slovak Republic

⁴Department of Histology and Embryology, Faculty of Medicine, University of Ostrava, Ostrava – Vítkovice, Czech Republic

ABSTRACT

Heat stress exerts a negative impact on the production indicators of animals and, can, threaten their lives. The aim of this study is to document and describe macroscopic, as well as microscopic findings in laying hens who died because of heat stress during the summer heat. This is a sample of 14 laying hens which were selected from mass mortality events in poultry farming businesses. The cause of death was cardiorespiratory failure caused by overheating. Characteristic macroscopic findings were scalp cyanosis, skeletal muscle anaemia with a cooked-meat-like appearance, petechiae and hyperaemia of internal organs. Microscopic examination revealed venostasis, with dilated blood vessels overfilled with erythrocytes. The diagnostic findings document hyperaemia, cyanosis, a cooked meat-like appearance, noticeable venostasis of internal organs and intravascular haemolysis. These findings resulted from pathological conditions that developed gradually in a warm environment and led to death. The pathophysiology and changes that develop as a consequence of high temperatures are discussed. This article could be useful for veterinary pathologists diagnosing deaths caused by prolonged exposure to extraneous environmental high temperatures.

Key words: poultry farming; laying hen; overheat; heat stress; thermoregulation; veterinary pathology

INTRODUCTION

Livestock breeding is determined by several factors, with environmental conditions being one of the basic prerequisites. Temperature parameters have a significant impact on growth rate, production, and welfare. The presence of kind specifications is, also, reflected in differences in heat tolerance. Heat stress can be defined as the sum of the external pressure acting on the animal so that it causes a rise in the body's internal temperature with a physiological response (Kim *et al.*, 2024). It can be concluded that recent decades have seen warmer weather, and average annual temperatures

can be expected to continue rising. This also applies to Europe, with longer periods of warm weather, becoming a common part of our summer, increasing duration of temperature as well as their intensity (Výberčí and Pecho, 2018). These facts are reflected in the veterinary and zootechnical practice of professional breeders, who must consider mechanisms for the ventilation, heating, and cooling of the air in intensive breeding setups. Not all animals can withstand high temperatures in their environment, which is a concern especially for livestock in breeding farms. If we compare the mechanisms, in our climate conditions, air needs to be heated for around 150 – 180 days/year and cooled for 30 – 50 days/year

Copyright: © 2025 Makovický *et al.*

***Correspondence:** E-mail: pmakovicky@email.cz

Peter Makovický, Biomedical Research Center, Slovak Academy of Sciences, Cancer Research Institute, Bratislava, Slovak Republic

Received: February 17, 2025

Accepted: March 31, 2025



(Debrecéni *et al.*, 2008). Raising chickens and laying hens requires a temperature of up to 24 °C with a humidity of 60 – 75 %. According to theory that, if the temperature rises to 30 °C, feed intake decreases. If the temperature reaches 35 °C, the consequences of lower production are detected, while a temperature above 38 °C is critical, with total exhaustion of the organism and death (Mangan and Siwek, 2023). Heat stress of laying hens is thus manifested in all parameters, with reduced feed intake, deterioration of feather quality and reduction of egg laying. Laying hens are irritated, panting with their beaks open, and their combs are heavily blood-stained. Since we encounter cases of death due to the heat stress in our practice, making it a current issue, here we present some of our results regarding pathological changes. Even though the mechanisms of death by exposure to prolonged and excessive heat are known, the affected organs, interspecies differences, genetic background, possible effects on production, and finally also preventive aspects are still discussed in the professional literature. The aim of our work is to describe the macroscopic and microscopic findings that arose because of thermal stress on dead laying hens. The findings could be applied in the practice of veterinary pathologists in the assessment and interpretation of individual changes in animals that died under the influence of heat. The results could also be helpful for the wider professional public when considering the risks in the course of

sudden or longer-lasting heat, as well as the economic impact on laying hens. At the same time, we draw attention to the underestimation of cooling during the summer months with a reduction in production and the possibility of the death of laying hens.

MATERIAL AND METHODS

In 2023 and 2024, during the summer months, we received selected bodies of dead laying hens from 5 independent poultry farms for the purpose of pathological examinations (Figure 1C, 1D, 2A). It was a sudden death on farms, which sent some bodies for necropsy and altogether we examined samples from 14 laying hens. We received carcasses each time from individual subjects (2 bodies/first farm; 2 bodies/second farm; 2 bodies/third farm; 4 bodies/four farm; 4 bodies/five farm). The autopsies were performed with an external and internal inspection and the collection of material for histopathological examination, including dissections of samples from skeletal muscles of the breast and thigh, small intestines, liver, kidneys, lungs, hearts, and brains. Samples were fixed in 10 % neutral buffered formalin for 24 – 48 hours and afterward processed by a standardized histological technique using automatized lineal tissue processor (ATP 1000 Tissue Processor, Histo-Line Laboratories, Italy) with default program of dehydration and paraffin baths.



Figure 1. Delivered corpses of laying hens with the weight (A, B, C, D).

Samples were embedded in paraffin blocks using an embedding station (Paraffin embedding centre TES 99, Medite, Germany). Blocks were sliced into serial tissue sections of 3–4 μm and stained with haematoxylin-eosin staining (Bamed, Czech Republic). Samples were mounted with Pertex, analysed by light microscopy at various magnifications, and bright-field images were acquired with an Olympus BX46 (Japan) microscope and an Olympus U-CMAD3 camera.

RESULTS

Macroscopic findings

There were well-preserved feathered laying hens in a clutch with an average weight of 3.72 kg (3.2–4.0 kg), which were fed with a feed mixture (Figure 1A, 1B). The findings are dominated by hyperaemia of the comb and lobules with cyanosis on its peripheral parts (Figure 2B). The skin of the head was cyanotic (Figure 2C). Anaemia of the skeletal muscles, sometimes the skeletal muscles had the appearance of "cooked meat", being whitish in appearance with numerous petechiae and superficial hematomas (Figure 2D, 2E, 2F, 2G, 2H, 2I). Beak cavities were smeared with blood. The digestive tract differed only in the degree of digestion with

the presence of a feed mixture in the glandular and muscular stomach with the possible presence of light-yellow watery content (Figure 3A, 3B). Intestines with contents of a pasty consistency of light-brown colour with alternating contents of lighter to dark green liquid and with segmental tympany of the intestines and occasionally visible bleeding on the intestinal mucosa (Figure 3C). The livers were light-red colour with a stiffer but crumbly consistency with signs of steatosis and dilated gall bladders (Figure 3D). The mucous membranes of the trachea were smeared with blood with some foamy bloody contents. The presence of oedema, lung hyperaemia, and lungs soaked with blood (Figure 3E, 3F) were observed. Moreover, there was superficial bleeding on the surface of the hearts and clotted blood in heart cavities. A small amount of unclothed blood was occasionally visible in the abdominal cavities (Figure 3G). Kidneys were oedematous and hyperaemic, and the spleen was enlarged. Increased functional fat in the abdominal cavity was noticed. There was a hyperaemia of brain tissue. All hens were laying, with the presence of eggs in various stages of development (Figure 3H, 3I). The conclusion was that the cause of death was cardio-respiratory failure after overheating of the body.

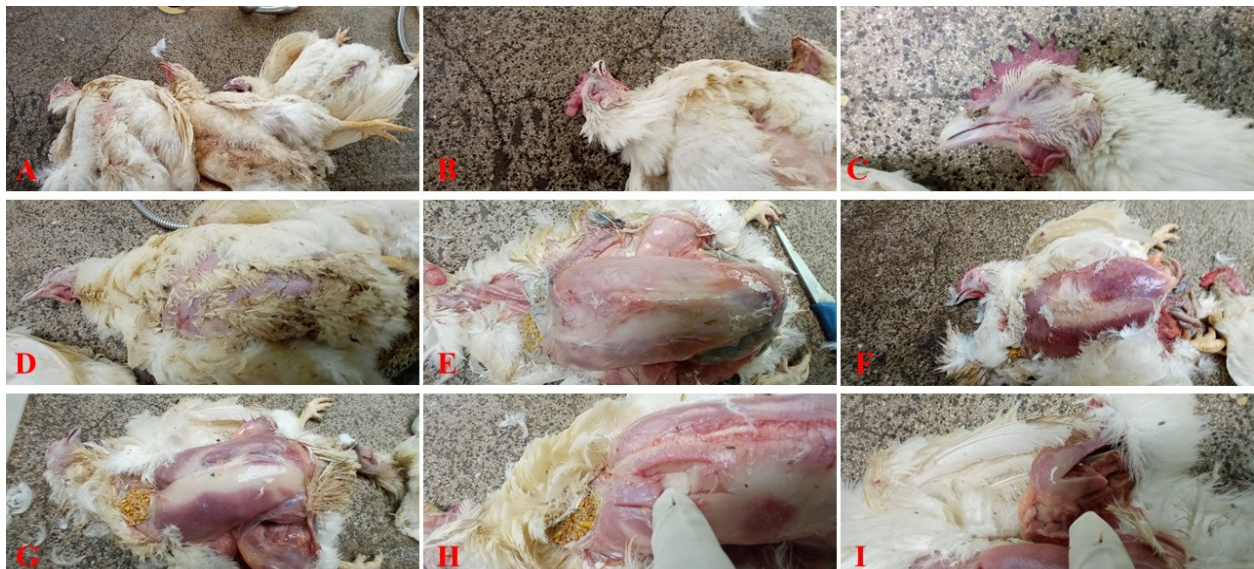


Figure 2. View of several dead hens (A) with well-perfused combs and a bluish tinge to the skin in the head area (B, C). The bodies are feathered with naturally thinned feathers in the chest area (D) with pectoral muscles that give the impression of cooked meat (E) and with larger or smaller dark-red coloured skeletal muscles (F, G). Sampling of breast (H) and thigh (I) muscles.

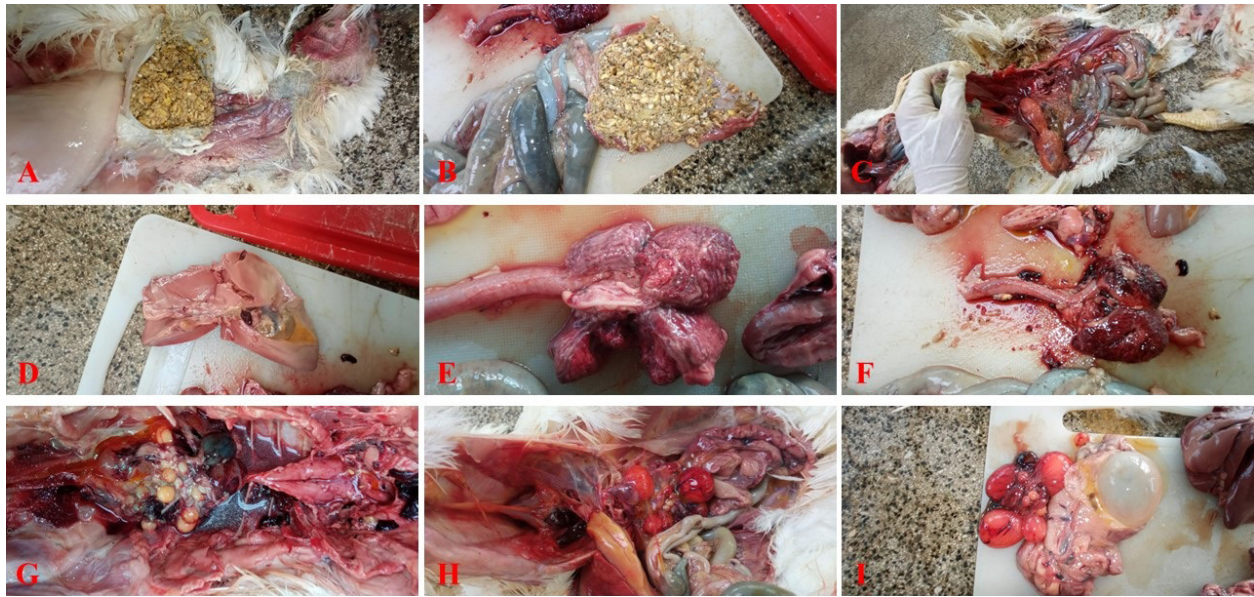


Figure 3. Laying hens fed with a feed mixture (A). The entire intestinal contents are coloured by alternating lighter, darker, and more noticeably reddened sections (B, C). The liver is light in colour imitating steatosis (D). Lightly reddened trachea and conspicuously congested or haemorrhagic lungs (E, F). After extraction of internal organs, some unclothed free blood (G) remains in the body cavity and numerous eggs in various stages of development are present (H, I).

Microscopic findings

Skeletal muscles: predominantly transversely cut, pinkish, sometimes purple shaded skeletal muscle fibers, which are ovoid-to-angular in shape with minor size differences, with a captured shift of the nuclei to the centre and, in places, individual degeneration (Figure 4A, 4B, 4C). Noticeable venostasis was present throughout the material with intravascular haemolysis and several miniature brown-black granules were visible (Figure 5A). At points of contact with muscle fibers, compressed and clumping endomysium with optically empty spaces (Figure 4D, 4E, 4F) were observed. Slightly loosened interstitial spaces with a digested to lumpy connective tissue component with fragmentary, broken, preserved collagen beams (Figure 4G, 4H, 4I) were present.

Hearts: transversally cut hearts exhibited slight loosening, because of autolysis initially digested, cardiomyocytes with numerous clearly visible vessels, which are crowded with a population of vital erythrocytes and several disintegrating erythrocytes. Capillaries were cracked in some places with the presence of vital erythrocytes in the stroma. In the heart cavities, masses of vital erythrocytes and disintegrating erythrocytes,

including granules were observed. Fatty degeneration of the myocardium (Figure 5B) was present.

Small intestines: advanced autolysis of small intestine with contours of the original digested relief of the villi and preserved vessels that are replete with a population of erythrocytes with mass of brown-black granules (Figure 5C) were noticed.

Livers: hepatocytes, which are preferentially arranged in pseudo-glandular formations, part of which were regressively changed with the presence of a few optically empty vacuoles with the character of fatty degeneration and the finding of microvesicular steatosis. Slightly dilated spaces between hepatocyte trabeculae with the presence of numerous thin-walled vessels that were crowded with a population of vital erythrocytes and decomposing erythrocytes were present. In some areas, a little accumulated dark material (Figure 5D) were noticed.

Spleens: a preserved structure in the spleen was manifest with areas of clumped groups of disintegrating erythrocytes with a some hemosiderin was observed.

Brains: transversely sectioned brains with captured cerebellum exhibited slightly loosened structure and compressed to vacuolated stroma with thinned up cells were present.

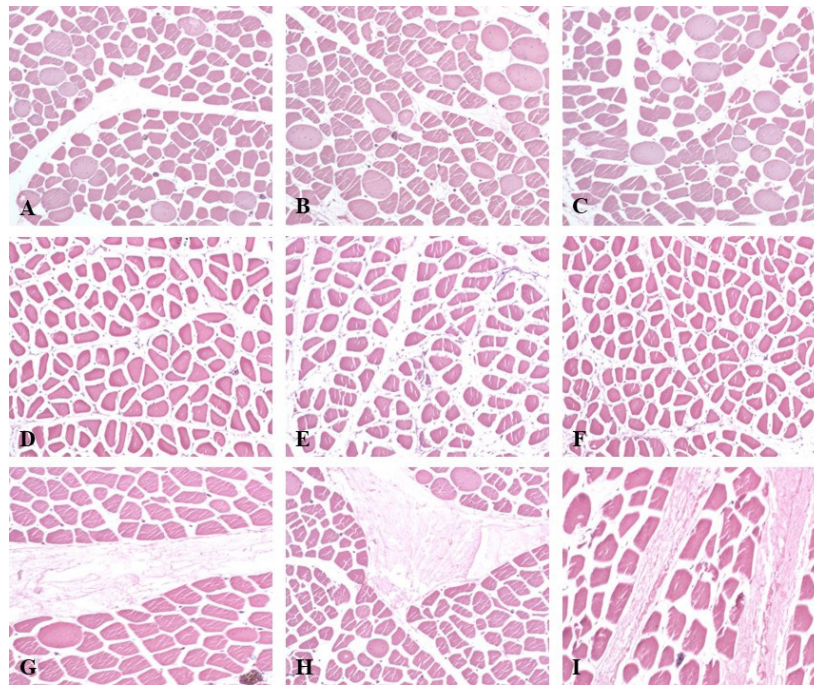


Figure 4. Histological appearance of transversely sectioned skeletal muscles with the presence of slight disproportionality in the thickness of individual muscle fibers (A, B, C), slightly crushed endomysium (D, E, F), and loose, digested to clumping ligament with remnants of vital collagen fibers (G, H, I). Legends: A-I: HE: 100x.

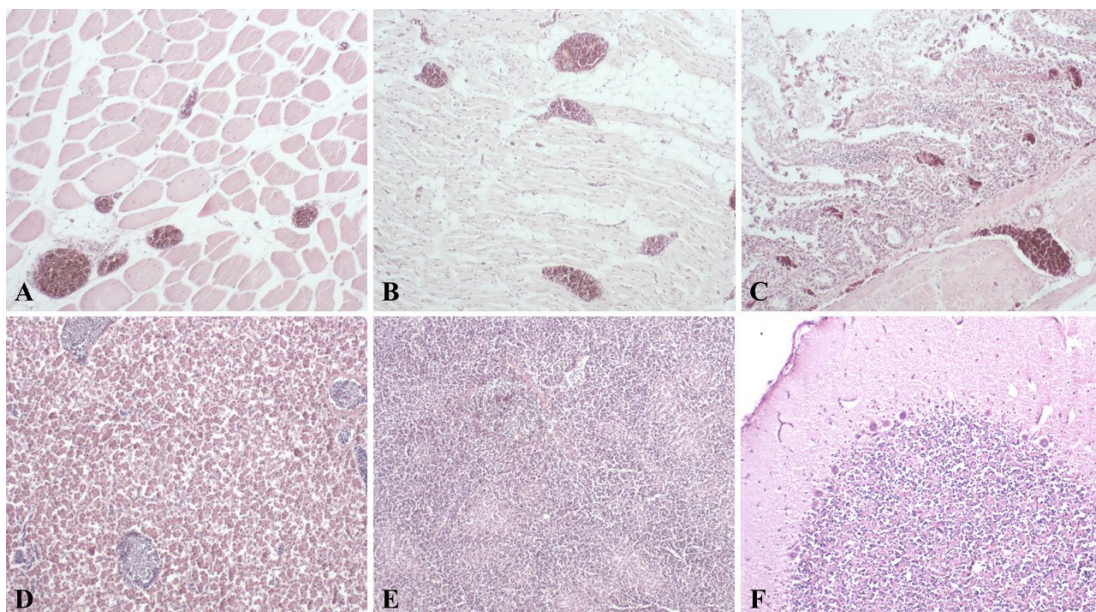


Figure 5. The venostasis dominates in the whole material with the presence of numerous erythrocytes in the vessels (A). Other findings include fatty degeneration of the heart muscle (B), advanced autolysis of the small intestine (C). Liver with an image of finely crushed trabeculae of hepatocytes (D), preserved structure of spleen with clusters of erythrocytes (E), and view of cerebellum with trapped layers (F). Legend: A-F: HE: 100x.

DISCUSSION

As a result of the combination of the prolonging of warm days with the growth of heat intensity and genetically modified efficiency, there is a naturally higher sensitivity to heat of livestock in intensive farms. This also applies to the breeding of laying hens, while certain differences have already been proven in this regard (Tamzil *et al.*, 2013). Heat stress in poultry breeding is clinically manifested by slower movement with outstretched wings, crouching to the floor, increased water consumption, reduced feed intake, accelerated breathing, changes in skin colour, and finally increase in mortality (Abo-Al-Ela *et al.*, 2021; Pereira *et al.*, 2010). It can be stated that laying hens can partially adapt to higher temperatures, while their naturally higher body temperature gives them the assumption of a certain resistance to higher temperatures. Their feathers also help them in this and fulfil the function of insulation against lower but also higher temperatures. At the same time, during higher temperatures, they can effectively increase blood flow in the lobes and combs with the ability to release heat to the surroundings. On the other hand, the absence of sweat glands makes it impossible for them to transfer heat to the surroundings in the form of sweating (Basaki *et al.*, 2020). In addition, if they are concentrated in the space, they mutually heat the air with a lower ability to transmit heat to the surroundings. These facts then contribute to deaths in an environment of high temperatures, which also corresponds to the changes documented by us, which are comparable to findings in similar studies (Apalowo *et al.*, 2024). The pathophysiology of the process itself corresponds to the causally accelerating metabolism with higher demands for oxygen consumption. Over time, their breathing deepens with the onset of shortness of breath. At the same time, blood vessels in the skin expand with a decrease in blood pressure. In particular, the demands on the cardiovascular system are increasing. The risk of the failure of individual internal organs due to a lack of oxygen and low blood pressure increases. A whole spectrum of fundamental changes can occur, such as kidney and liver failure, blood clotting disorders but also the breakdown of erythrocytes. Nerve cells are the most sensitive to the lack of oxygen, followed by muscle and epithelial cells, while the most resistant are connective tissue cells. In the pathology documented by us, the brains and cerebellums are

affected by slight swelling of the stroma, eventually also with vacuolization and the presence of oedema with slightly crushed or thinned nerve cells. Part of view is affected by autolysis, but part is results of primary pathology. As reported by Srivastava *et al.* (2022), the main postmortem finding is dehydration and conspicuously faded skeletal muscles with the characteristic appearance of cooked meat. This was noticeable in our cases as well, while in addition, we macroscopically document also smaller or darker-coloured skeletal muscles merging with each other. Continuous shortness of breath is involved in the increase of anaerobic glycolysis also with the increase of lactate concentration in the muscles. As a result of heat stress, there is an increase in reactive oxygen species with an increase in oxidative stress and an impact on the structure of enzymes in the sarcoplasmic reticulum with the release of corticosteroid hormones that reduce calcium resorption and increase its excretion (Zaboli *et al.*, 2019). It is known that nerve-mediated depolarization of the membranes of the sarcoplasmic reticulum causes, under normal conditions, the passive transfer of calcium molecules from the sarcoplasmic reticulum, which subsequently comes into direct contact with muscle filaments and the formation of muscle contraction (Makovický *et al.*, 2008). However, the actin-myosin connection itself is only disconnected after the binding of ATP to myosin. In all the cases documented by us, the pectoral and thigh muscles were macroscopically damaged with the appearance of pale, cooked meat and with the presence of areas merging into each other into dark-red coloured areas. At the same time, laying hens are predisposed to cardiovascular failure due to the rapid growth of adipose tissue, which is abundantly vascularized with a natural increase in blood volume. However, the hearts themselves are postnatally no longer able to increase their volume and thus remain exposed to higher demands. In all our cases, these were heavier laying hens with naturally higher demands on metabolism. Although the microscopic structure of individual organs was marked by initial autolysis, the causal changes were recognizable. Taking into account the mentioned facts, it came to blood thickening as a result of dehydration, with slower circulation and at the same time a lower level of oxygen exchange, which put more pressure on the heart's activity. According to one study, where several tissues were tested, heat stress had the most intense effect on lung homeostasis,

with pneumonia, emphysema, and haemorrhages being found (Nan *et al.*, 2023). Macroscopically, these findings correlate with ours but we did not perform a microscopic examination of the lungs. Here need to noted, we are a clinical pathology department, we do not have the same conditions as scientific workplaces. We did not receive the bodies immediately after death. However, other clinical pathology workplaces also struggle with such problems. They must be able to diagnose the primary cause of death. Due to the predicted increasing temperature conditions, heat stress has already become part of the management of veterinarians and zootechnicians (Onagesan *et al.*, 2023). They also struggle with this problem abroad. For example, more than 1 million chickens die from heat stress in the UK, and more than 20 million livestock in the US annually. A report from the UK states that more than 10,000 chickens died during transport to the slaughterhouse in just one day as a result of the temperature rising to 40 °C. Despite the fact that this problem has already entered the undergraduate syllabi of our universities, we believe that more attention should be paid to it. This is not just about therapy, prevention of production-reduction or losses but about a complex approach to the problem from the point of view of strengthening the resistance of animals, then the special properties of housing, including procedures for the construction of such spaces, technologies, methods of bedding and feeding feed or medicines. In the future, these facts could be part of the modernization of farming, as well as the welfare of exotic animals.

CONCLUSION

Heat stress is a serious danger in intensive farming, as a large amount of poultry die each year. It is indisputable that the veterinary as well as the breeding public must consider this problem. Here, on the basis of a selected sample of 14 laying hens that died as a result of heat stress, we documented the selected macroscopic and microscopic findings. The cause of death was cardiovascular failure. Macroscopic and microscopic findings and mechanisms that contributed to the death are discussed. The diagnostic findings document hyperaemia, cyanosis, cooked meat, noticeable venostasis of internal organs and intravascular haemolysis. These could serve the wider

professional public in the differential diagnosis of the causes of death, promoting better therapeutic and breeding procedures, whilst, also, suggesting preventive measures to mitigate heat stress.

ACKNOWLEDGEMENT

Thanks to Simone Charlesworth for proof-reading and English grammar corrections.

This work was supported by VEGA grant 2/0121/21.

AUTHOR'S CONTRIBUTIONS

Conceptualization: MAKOVICKÝ, Pavol, MAKOVICKÁ, M.

Methodology: MAKOVICKÝ, Pavol, MAKOVICKÁ, M.

Investigation: BOLGÁČ, P., MAKOVICKÝ, Peter

Data curation and supervision: JAKIČ, K., MAKOVICKÁ, M.

Writing-original draft preparation: MAKOVICKÝ, Pavol

Writing-review and editing: BOLGÁČ, P., MAKOVICKÝ, Peter

Project administration: JAKIČ, K.

All authors have read and agreed to the published version of the manuscript.

DATA AVAILABILITY STATEMENT

The data presented in this study are available on request from the corresponding author.

CONFLICT OF INTEREST

The authors declare no conflict of interest.

REFERENCES

- Abo-Al-Ela, H. G., El-Kassas, S., El-Naggar, K., Abdo, S. E., Jahejo, A. R. & Al-Wakeel, R. A. (2021). Stress and immunity in poultry: light management and nano-technology as effective immune enhancers to fight stress. *Cell Stress Chaperones*, 26, 457–472.
- Apalowo, O. O., Ekunseitan, D. A. & Fasina, Y. O. (2024). Impact of heat stress on broiler chicken production. *Poultry*, 3, 107–128.
- Basaki, M., Sahraiy, N., Kezkavusi, K., Akbari, G., Shahbayfar, A. A. & Klanifard, D. (2020). Differential expression of small heat shock proteins in the brain

- of broiler embryo; the effects of embryonic thermal manipulation. *Journal of Thermal Biology*, 93, 102719.
- Debrečeni, O., Mlynek, J., Bulla, J., Juhás, P. & Bobček, B. (2008). The animal welfare application in rural development plan in Slovakia. *Journal of Central European Agriculture*, 9, 809–816.
- Kim, H. R., Ryu, Ch., Lee, S. D., Cho, J. H. & Kang H. (2024). Effects of heat stress on the laying performance, egg quality, and physiological response of laying hens. *Animals*, 14, 1076.
- Makovický, P., Makovický, P. & Jílek, F. (2008). Short review of some properties of muscular proteins. *Československá fyziologie*, 57, 10–14.
- Mangan, M. & Siwek, M. (2023). Strategies to combat heat stress in poultry production – A review. *Journal of Animal Physiology and Animal Nutrition (Berl)*, 108, 576–595.
- Nan, J., Yang, H., Rong, L., Jia, Z., Yang, S. & Li, S. (2023). Transcriptome analysis of multiple tissues reveals potential mechanism of death under acute heat stress in chicken. *BMC Genomics*, 24, 27–31.
- Onagesan, O. M., Uzanga, V. A., Oso, O., Tona, K. & Oke, O. E (2023). Alleviating heat stress effects in poultry: updates on methods and mechanism of actions. *Frontiers in Veterinary Science*, 10, 1255520.
- Pereira, D. F., do Vale, M. M., Zevolli, B. R. & Salgado, D. D. (2010). Estimating mortality in laying hens as the environmental temperatures increases. *Brazilian Journal of Poultry Science*, 12, 265–271.
- Srivastava, S. (2022). Heat stress in chicken. *Acta Scientifical Veterinary Sciences*, 4, 59–61.
- Tamzil, M. H., Noor, R. R., Hardjosworo, P. S., Manalu, W. & Sumantri C. (2013). Acute heat stress responses of three lines of chickens with different heat shock protein (HSP)-70 genotypes. *International Journal of Poultry Science*, 12, 264–272.
- Výberčí, D. & Pecho, J. (2018). Letné periódy teplého počasia v období 1951 – 2017 na Slovensku, identifikované s využitím priestorových hodnôt teplotných charakteristík. *Meteorologický časopis*, 21, 31–38.
- Zaboli, G., Huang, X., Feng, X. & Ahn, D. (2019). How can heat stress affect chicken meat quality? – A review. *Poultry Science*, 98, 1551–1556.