

*Short communication*

## DISTRIBUTION OF TISSUE LIPOPROTEIN LIPASE ACTIVITY IN FELINE BULBOURETHRAL GLAND STRUCTURES

R. DIMITROV

Trakia University, Stara Zagora, Bulgaria

---

### ABSTRACT

The aim of the present study was a demonstration of LPL activity and localization in feline bulbourethral glands. The glands of seven sexually mature, clinically healthy European shorthair male cats, aged 12-18 months, weighing 2.8-4 kg, obtained from a licensed animal breeder were investigated in the present study. Cryostat cross sections of 5-7  $\mu\text{m}$  were used for enzyme histochemical detection of lipoprotein lipase (LPL) by the Gomori Tween method. The reaction was positive when clusters of dark-brown lead sulfide precipitates were present. The localization of tissue LPL expression was determined by light microscopy. The intensity of the reaction was assessed by a semi-quantitative analysis using the score system. In the present study, high LPL activity was detected in apical parts of the bulbourethral glandular epithelium and in the lumen of glandular tubules. A medium activity of LPL expression was present in the basal parts of parenchymal epithelial cells. No LPL activity was found out in the muscular layer of bulbourethral glands' capsule, whereas in the stroma, where smooth muscle tissue was predominating, the LPL enzyme activity was low.

**Key words:** lipoprotein lipase; bulbourethral glands; tomcat

---

### INTRODUCTION

Lipoprotein lipase (LPL) is an enzyme catalyzing the hydrolysis of triglyceride components of circulating chylomicrons and low-density lipoproteins (Doolittle *et al.*, 1999; Mead *et al.*, 2002). The deviations in LPL function are related to various pathological states, atherosclerosis, chylomicronaemia, obesity, Alzheimer's disease, dyslipidaemia and etc. in men. The activity of LPL is dependent upon the type of nutrition, the physiological condition, and is altered throughout various diseases. It is established that LPL is synthesized by all tissues, but the highest amount of the enzyme is detected in white

and brown adipose tissues, the liver of the neonate and the brain. The enzyme is synthesized by the heart, brain and neonatal liver cells, whereas endothelial cells are responsible for its excretion.

LPL is formed and released by various cell types, among which are the endothelial cells of capillaries. In the adipose tissue and muscles, the enzyme is produced and released in a catalytically active form from adipocytes and myocytes, and then it is transported to the surface of the capillary endothelium (Pentikäinen *et al.*, 2002). Together with pancreatic, spleen and endothelial lipases, LPL belongs to the group of triglyceride lipases in mammals.

---

\*Correspondence: E-mail: rosiros38@abv.bg  
Rosen Dimitrov, Department of Veterinary Anatomy, Histology and Embryology,  
Faculty of Veterinary Medicine, Trakia University, 6000 Stara Zagora, Bulgaria  
Tel.: +421 37 6546285 Fax: +421 37 6546189

Received: May 18, 2011  
Accepted: January 30, 2011

In guinea pigs, Camps *et al.* (1990) have investigated LPL synthesis and expression in the glomerules, and provided evidence that the enzyme was converted to a catalytically active form in vascular endothelial cells, whereas its synthesis occurred in smooth muscle cells, the tubuloalveolar glands' epithelium and parenchymal cells.

Ruge *et al.* (2004) showed the relationship between kidney disorders, lipoprotein metabolism and LPL activity in renal tissue in minks, mice, Chinese hamsters and rats. The highest LPL activity was observed in the kidneys of minks, followed by the other three rodent species. By means of immunohistochemistry, the authors found out that LPL was produced in the epithelium of renal tubules.

The endothelial form of LPL is important for the reproduction in mammals (Lindegaard *et al.*, 2005). In adult mice, the expression of the enzyme was the strongest in the ovaries of pregnant animals, in placenta and testes. The highest LPL activity was observed in spermatozoa precursors in testes and in mature male sex cells in the epididymis.

Steals *et al.* (1996) provided evidence for the key role of LPL in the energy and lipid metabolism of adrenal glands in men and for its participation in steroidogenesis. The authors established LPL in the cortex of foetal and postnatal adrenal glands. In these organs, the regulation of LPL enzyme activity was performed by factors, catalyzing adrenal steroidogenesis.

The activity of tissue LPL in the mammary glands in rodents was found out to play a primary role in the synthesis of milk secretion, and was negatively correlated with the ovarian hormone stanniocalcin. After application of this hormone, tissue triglyceride concentrations in the gland were reduced but serum ones increased due to the reduced activity of glandular LPL (Zaidi *et al.*, 2006).

Studying the semen plasma of goats, Sias *et al.* (2005) proved that lipase, secreted by bulbourethral glands, is responsible for the death of spermatozoa consequently to the toxic effect of free fatty acids.

The lack of information about the localization of LPL activity in feline bulbourethral glands and about the role of this enzyme in pathological alterations of this gland, have raised our interest for performing the present enzyme histochemical investigation. With this, we aimed at detecting the various tissue zones in the normal bulbourethral glands in cats, where LPL was expressed.

## MATERIAL AND METHODS

The bulbourethral glands of 7 sexually mature, clinically healthy European shorthair cat males at the age of 12–18 months and weighing 2.8 to 4 kg were used. The animals were obtained from a licensed

animal breeder. Cats were euthanized with intravenous injection of 50 mg/kg Thiopental 1g (thiopental sodium, Sandoz, Kundl-Austria) into the cephalic vein. The material for the study was obtained immediately after opening of abdominal and pelvic cavities and removal of bulbourethral gland. The experiment was carried out under strict observance of the European Convention for the Protection of Vertebrate Animals used for Experimental and Other Scientific Purposes, the *European Convention for the Protection of Pet Animals*, and Law on Animal Protection in the Republic of Bulgaria – part IV (Experiments with animals, art 26, 27, 28), part VII (Euthanasia of Animals, art. 45, 46, 47, 48) and part VIII (Protection and welfare of animals, art 52, 53).

After careful removal with the aid of a magnifying glass, pieces of the bulbourethral glands (1 cm<sup>3</sup>) were frozen in a cryostat at –20 °C and used for enzyme histochemical detection of LPL by the Tween method (Pearse, 1962) as follows: preparation of cryostat cross sections of 5–7 µm and fixation in 10% neutrally buffered formalin for 10 min, washing with distilled water, put with the incubation medium into a thermostat for 24 hours at 37 °C, washing with distilled water and treatment with 1% lead nitrate in a thermostat at 56 °C for 10 min, washing with distilled water and treatment with 1% yellow ammonium sulfide until lead sulfide precipitate (clusters of dark brown granules) appears. The reaction was considered as positive when clusters of dark brown precipitate were visible.

The localization of tissue LPL expression was determined by light microscopy (Primo Star (Zeiss, Germany), and the results were recorded with a Prog Res CT3 digital camera (Germany).

The intensity of the reaction was assessed semi-quantitatively using the score system of Atanassova (2000): 0 – lack of enzyme activity; + – weak enzyme activity; ++ – medium enzyme activity and +++ – strong enzyme activity.

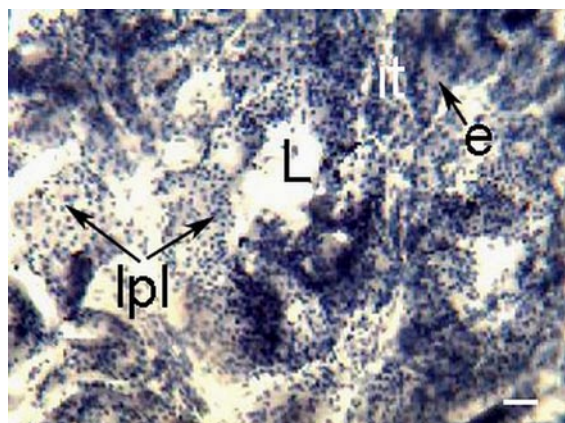
## RESULTS

The enzyme histochemical investigation for feline bulbourethral glands showed a high intensity of tissue LPL activity in the apical parts of the glandular epithelium and the lumen of glandular tubules. A medium expression of the enzyme was observed in the basal parts of parenchymal epithelial cells. No LPL activity was detected in the skeletomuscular gland capsule. In the stroma, where smooth muscle tissue prevailed, the LPL activity was weak (Table 1).

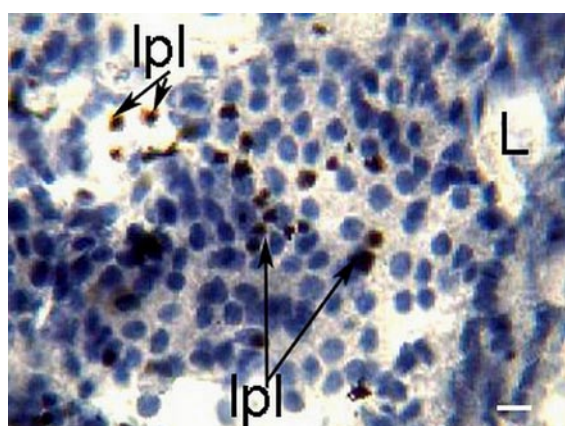
**Table 1: Intensity of the reaction for detection of lipoprotein lipase activity in the bulbourethral glands in male cats**

Bulbourethral glands	0 - lack of activity	+ weak activity	++ medium activity	+++ strong activity
Capsule	0			
Stroma		+		
Parenchyma – basal part of epithelium			++	
Parenchyma – apical part of epithelium				+++

LPL activity was expressed mostly in the glandular epithelial cells and in the tubular lumen with predominant localization in the apical parts of the epithelium unlike its basal parts (Figs. 1 and 2).

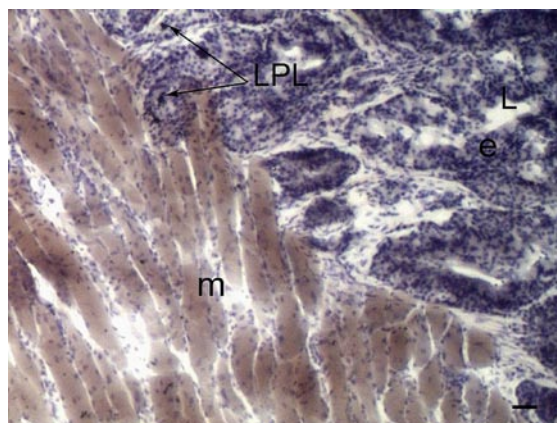


**Fig. 1:** An area of the bulbourethral gland, showing the localization of lipoprotein lipase (lpl) expression in basal and apical parts of glandular parenchyma (e), glandular interstitium (it), tubular lumen (L). Gomori staining. Bar =20 µm.



**Fig. 2:** An area of the bulbourethral gland, showing the localization of lipoprotein lipase (lpl) expression in the epithelial cells of glandular parenchyma, the tubular lumen (L). Gomori staining. Bar=10 µm.

In the glandular capsule, where skeletal muscle was prevailing, the LPL activity was not present in contrast to glandular stroma, where the LPL expression was rarely observed (Fig. 3).



**Fig. 3:** An area of the bulbourethral gland, showing the localization of lipoprotein lipase (lpl) expression in the epithelial cells of parenchyma (e), muscular layer (m), tubular lumen (L). Gomori staining. Bar=40 µm.

## DISCUSSION

The present study is the first one describing a considerable occurrence of the LPL expression in feline bulbourethral glands with a prevalence of the enzyme activity in the epithelial cells of the glandular parenchyma.

The apical epithelial localization of the LPL expression was probably related to lipid metabolism in this part of the gland, whereas the presence of enzyme activity in the lumen suggests about a possible role of LPL in the synthesis and transportation of lipid components of the bulbourethral secretion. These data correspond to the studies of Doolittle *et al.* (1999), Pentikäinen *et al.* (2002) and Mead *et al.* (2002) about LPL activity in human. Therefore, a similar relationship between deviations in the LPL expression in feline bulbourethral glands and

pathological changes in adipose tissue of cat males could be expected.

The results of Sias *et al.* (2005), showing that the lipase secreted by bulbourethral glands in goats caused necrospemia, allow us to assume that in cat males LPL could also play a key role in semen quality.

In this study, the LPL expression was detected in the bulbourethral epithelium and a less strong expression in the smooth muscle stroma, similarly to the data reported by Camps *et al.* (1990), where the LPL expression and synthesis in smooth muscle cells and the glandular epithelium of tubuloalveolar glands in guinea pigs were reported.

Our results about the LPL activity in the bulbourethral epithelium are in concert with the data of Ruge *et al.* (2004) about the LPL synthesis in the epithelium of kidney tubules in mink, hamster and rat.

Comparing our data with those of Lindegaard *et al.* (2005) evidencing that the strong LPL expression in murine testes is important for reproduction, we may assume that in cats this enzyme can be also actively involved in bulbourethral secretion and, therefore, is essential for semen vitality.

Our data also correlate with investigations about the role of LPL in the energy and lipid metabolism of adrenal glands and steroidogenesis in humans (Steals *et al.*, 1996). As the investigated gland is androgen-dependent, it could be presumed that in cats, the studied enzyme can play the same role.

Keeping in mind the conclusions of Zaidi *et al.* (2005) about the key role of mammary LPL activity in the rodent secretion, we hypothesize that this enzyme may also be important for secretory processes in bulbourethral glandular parenchyma.

The results from the present study demonstrate some enzyme histochemical traits of bulbourethral glands. These data can be useful for further investigation of the adipose degeneration in this organ.

## REFERENCES

- ATANASSOVA, P. 2000. Histogenesis and differentiation of the subcutaneous adipose cells in the early embryogenesis of the human *in situ*. Dissertation, Medical University : Plovdiv, 2000, p. 65-68.
- CAMPS, L. – REINA, M. – LLOBERA, M. – VILARO, S. – OLIVECRONA, T., 1990. Lipoprotein lipase: cellular origin and functional distribution. *Am. J. Physiol. Cell Physiol.*, 1990, vol. 258, no. 4, p. 673-681.
- DOOLITTLE, M – OSNAT, B. 1999. Immunodetection of Lipoprotein Lipase: Antibody Production, Immunoprecipitation, and Western Blotting Techniques. *Meth. Mol. Biol.*, 1999, vol. 109, no. 2, p. 215-237.
- LINDEGAARD, M. – NIELSEN, J – HANNIBAL, J – NIELSEN, L. 2005. Expression of the endothelial lipase gene in murine embryos and reproductive organs. *J. Lipid Res.*, 2005, vol. 46, no. 3, p. 439-444.
- MEAD, J. – IRVINE, S. – RAMJI, D. 2002. Lipoprotein lipase: structure, function, regulation, and role in disease. *J. Mol. Med.*, 2002, vol. 80, p. 753-769.
- PEARSE, A. 1962. Lipases, Lipases methods. In: *Histochemistry, Theoretical and Applied*: J. & A. Churchill Ltd., London, 1962, p. 472-475, p888-889.
- PENTIKÄINEN – M. OKSJOKI – R. ÖÖRNI – K. KOVANEN, P. 2002. Lipoprotein lipase in the arterial wall: Linking LDL to the arterial extracellular matrix and much more. *Arterioscler. Thromb. Vasc. Biol.*, 2002, vol. 22, no.2, p. 211-217.
- RUGE, T. – NEUGER, L. – SUKONINA, V. – WU, G. – BARATH, S. – GUPTA, J. – FRANKEL, B. – CHRISTOPHERSEN, B. – NORDSTOGA, K. – OLIVECRONA, T. – OLIVECRONA, G., 2004. Lipoprotein lipase in the kidney: activity varies widely among animal species. *Am. J. Physiol. Ren. Physiol.*, 2004, vol. 287, no. 6, p. 1131-1139.
- SIAS, B. – FERRATO, F. – PELLICER-RUBIO, M. – FORGERIT, Y. – GUILLOUET, PH. – LEBOEUF, B. – CARRIERE, F. 2005. Cloning and seasonal secretion of the pancreatic lipase-related protein 2 present in goat seminal plasma. *Biochim. Biophys. Acta*, 2005, vol. 1686, p. 169-180
- STEALS, B. – MARTIN, G. – MARTINEZ, M. – ALBERT, K. – ONSURBE, J. – SALADIN, R – HUM, D. – REINA, M. – VILARO, S. – AUWERX, J. 1996. Expression and regulation of the lipoprotein lipase gene in human adrenal cortex. *J Biol. Chem.*, 1996, vol. 271, no. 29, p. 17425-17432.
- ZAIDI, D. – JAMES, K. – WAGNER, G. 2006. Passive immunization of lactating mice with stanniocalcin-1 antiserum reduces mammary gland development, milk fat content, and postnatal pup growth. *Am. J. Physiol. Endocrinol. Metabol.*, 2006, vol. 291, no. 5, p. 974-981.