

DIAZINON AND CADMIUM ACUTE TESTICULAR TOXICITY IN RATS EXAMINED BY HISTOPATHOLOGICAL AND MORPHOMETRICAL METHODS

M. ADAMKOVIČOVÁ*, R. TOMAN, M. CABAJ

Slovak University of Agriculture in Nitra, Slovak Republic

ABSTRACT

Morphometrical and histopathological analysis were used to evaluate quantitative changes in the testicular seminiferous tubule morphology in mature rats ($n = 40$) after an intraperitoneal administration of cadmium at single dose of 2 mg/kg body weight, diazinon at single dose of 20 mg/kg body weight, and cadmium-diazinon coexposure. 36 hours after an experimental administration, the testes from all treated animals showed disorganization of tubular elements, with increased intercellular space, disruption of blood-testis barrier resulting in oedema, ischaemia and seminiferous tissue necrosis. A significant decrease in relative volume of seminiferous epithelium and tubule lumen ($P < 0.05$), significant increase of intraepithelial spaces in epithelium ($P < 0.05$), significant widening of the interstitial tissue ($P < 0.05$) in all experimental groups and significant dilatation of blood vessels in cadmium-treated animals ($P < 0.05$) confirmed the histological data. In rats, administration of cadmium caused necrosis of the testes due to vascular collapse. Diazinon administration and cadmium-diazinon coexposure led to different degrees of degenerative changes in seminiferous tubules. Cadmium and diazinon act as testicular toxicants disrupting male reproduction and their exposure may pose the risk of fertility disorders in animals and men. Results did not indicate synergistic or additional effect of simultaneous administration of cadmium and diazinon to the rat testis. Further experimental research is needed for detailed knowledge on reproductive toxicity of cadmium and diazinon interaction, particularly their long-term exposure.

Key words: cadmium; diazinon; testicular histopathology; morphometry; rat

INTRODUCTION

Environmental reproductive health focuses on exposures to environmental contaminants (synthetic chemicals and metals) and their potential effects on all aspects of reproductive health. Humans are exposed daily to a mixture of environmental contaminants in air, water and food. To understand the body burdens of environmental contaminants, knowledge on the health risk associated with current patterns of exposure is needed, including increased risk resulting from exposures to multiple chemicals (Woodruff et al., 2008). The toxicological profiles involve an examination,

generalization and interpretation of available toxicological information and epidemiologic evaluations of a hazardous substance. For over a century, laboratory animals have been used to predict the human health effects of various environmental contaminants. Although each species has its unique attributes, substantial conservation exists in the underlying molecular, cellular, and physiologic systems associated with vertebrate reproduction (Guillette and Edwards, 2008).

Cadmium (Cd) is a toxic metal occurring in the environment naturally and as a pollutant emanating from industrial and agricultural sources (Järup and Åkesson, 2009). Exposure to cadmium occurs as a

*Correspondence: E-mail: adamkovicova.maria@gmail.com
Mária Adamkovičová, Department of Veterinary Disciplines, Slovak University of Agriculture, Tr. A. Hlinku 2, 94976 Nitra, Slovak Republic
Tel.: +421 37 641 4466

Received: May 11, 2010

Accepted: June 14, 2010

result of atmospheric emission during Cd production and processing, from combustion of fossil energy sources, waste and sludge, phosphate fertilizers, and deposition of waste and slag at disposal sites (Toman et al., 2009a). The general population is exposed to Cd via contaminants found in drinking water and food (ATSDR, 2008a). The average cadmium intake from food generally varies between 8 and 25 µg per day. The concentrations of cadmium in food vary considerably, but often foods of plant origin, such as cereals, potatoes, roots, and vegetables (Olsson et al., 2002) and the animal kidneys, wild mushrooms, and seafood such as mussels and oysters (Fried and Rozman, 2008) are the major contributors to the exposure. Therefore, limitation in their use should have been considered. The most recent derivation of a tolerable intake was undertaken in 2009 by the European Food Safety Authority's Panel on contaminants in the food chain (EFSA, 2009) and a tolerable weekly intake (TWI) for cadmium of 2.5 µg/kg body weight was established.

Cadmium has been found to produce a wide range of biochemical and physiological dysfunctions in humans and laboratory animals (Santos et al., 2004). It causes tissue damage in humans and animals, acting as an inducer of oxidative stress (Thompson and Bannigen, 2008, Tremellen, 2008, Turner and Lysiak, 2008) and an endocrine disruptor in humans and rodents. Highly toxic cadmium accumulates in the body over a lifetime and can adversely affect the mammalian male reproductive system (Lukáč et al., 2009). Except of endocrine and reproductive effects, cadmium exposure has been associated with nephrotoxicity, osteoporosis, neurotoxicity, carcinogenicity, genotoxicity and teratogenicity (EFSA, 2009; Kimáková et al., 2006). Rats exposed to cadmium manifested significant accumulation of cadmium in liver, kidney and muscle tissue when dosed intraperitoneally and in liver and kidney after a peroral administration (Toman et al., 2009a). Studies have illustrated that the testis is exceedingly sensitive to cadmium toxicity (Siu et al., 2009), associated with reduced male fertility, such as reduced spermatozoa count and poor semen quality, in men exposed to cadmium and other environmental toxicants (Benoff et al., 2000).

Diazinon (O,O-diethyl O-2-isopropyl-6-methyl pyrimidinyl-4-g-1-phosphorothioate) is a nonselective organophosphate insecticide primarily used for agricultural purposes and is released to the environment through spraying on a wide variety of agricultural crops and at agricultural sites for pest control (ATSDR, 2008b). Organophosphorus compounds are one of the most common types of organic pollutants found in environmental and food products (Tang et al., 2009), and since diazinon is only used in agricultural setting because of the cancellation of residential uses in 2004, the main way in which the general public could be exposed is

via eating food treated with diazinon (ATSDR, 2008b). Diazinon can affect both animals and man even after a single exposure (Sarabia et al., 2009).

Toxicity of diazinon is realized through the inhibition of enzyme acetylcholinesterase whose biological role is the termination of impulse transmissions at cholinergic synapses within the nervous system by rapid hydrolysis of the neurotransmitter - acetylcholine (Schumacher et al., 1986). Attia and Nasr (2009) published results of the experiment where acetylcholinesterase activity in the serum of pesticide paraquat treated rats was significantly reduced. Besides the neurological effects of diazinon, reproductive effects leading to structural testicular changes in bluegill (Dutta and Meijer, 2003), mice (Piña-Guzmán et al., 2005) and rats (Toman et al., 2009b) have also been described.

In our study, cadmium and diazinon were chosen as the combination of reproductive toxicants for interaction profile because of their possible occurrence in the animal and human food and therefore they can pose the reproductive effects when ingested concomitantly. As the seminiferous tubules comprise approximately 80% of the testicular mass, the morphological measurements of seminiferous tubules are important in the studies of testis tissues (Hsieh et al., 2009).

MATERIAL AND METHODOLOGY

All experiments were carried out to alleviate the animal suffering in accredited laboratory (SK PC 50004, SUA Nitra). Forty mature, 4 months old male rats of the Wistar strain (weighing approximately 410 g) were randomly divided into four groups of ten animals. The males were housed individually in plastic cages under the same laboratory conditions of temperature (20-22 °C), relative humidity (55 ± 10 %), and a 12 h light/dark cycle with free access to food (feed mixture M3, Machal, Czech Republic) and drinking water. Rats in the group A were injected with a single dose (20 mg/kg b.w.) of diazinon (Sigma-Aldrich, USA, purity 99%) intraperitoneally in physiological solution, rats of the group B were injected a single intraperitoneal dose (2 mg/kg b.w.) of cadmium in the form of CdCl₂ (Reachem, Slovak Republic, purity 96%) in physiological solution, and rats in the C group were given a mixture of cadmium (2 mg/kg b.w.) and diazinon (20 mg/kg b.w.) intraperitoneally in physiological solution. The fourth group served as a control, received only physiological solution.

Animals were anaesthetized with ether and sacrificed 36 h following an experimental administration. The testes were immediately sampled, weighed and fixed in modified Davidson's solution (Latendresse et al., 2002). The fixed tissues were embedded in paraffin, sectioned at 5 µm, mounted on slides and stained with haematoxylin-eosine for microscopic examination.

Sections were subjected to morphological analysis and morphometric measurements based on computerized techniques with PC morphometric software M.I.S. Quick Photo and using light microscope Olympus AX 70 Provis (Japan). Relative morphometric parameters (%) for seminiferous epithelium, intraepithelial spaces, tubule lumen, interstitial tissue and blood vessels in the testes were evaluated. Comparisons between the groups were assessed by one-way analysis of variance (ANOVA) and *post hoc* Scheffe test using the Statgraphics Centurion XV software. Significant differences were calculated at the level of 0.05.

RESULTS AND DISCUSSION

Histological analysis of testes in the control group revealed well-developed circular or elliptical seminiferous tubules enclosed by a thick basal lamina. The tubules were lined with seminiferous epithelium

with active spermatogenesis, germ cells (spermatogonia, primary and secondary spermatocytes, spermatids) were organized in concentric layers and the tubular lumen was usually empty. At any stage of differentiation, the spermatogenic cells were in close contact with Sertoli cells, empty spaces within the seminiferous epithelium were rarely observed. Interstitial connective tissue was filled with interstitial Leydig cells, small blood vessels, collagen fibres and fibroblasts. The normal architecture of testicular seminiferous tubules and interstitial spaces is shown in figure 2.

Results of the morphometric evaluation of testes in control and experimental groups are presented in table 1 and figure 1. A number of animal studies revealed adverse reproductive effects on male reproductive system after an acute cadmium exposure, such as marked morphological changes in form of swelling, congestion, haemorrhage and necrosis in the testes of rats (El-Shahat et al., 2009). In our experiment 36 hours after the

Table 1: Morphometric evaluation of the testes from control and experimental rats (%)

Group	Seminiferous epithelium	Intraepithelial spaces	Tubule lumen	Interstitial tissue	Blood vessels
Control	64.82 ± 7.24	0.38 ± 1.02	23.58 ± 8.91	10.93 ± 4.31	0.29 ± 0.53
Cd	44.05 ± 8.10+	11.22 ± 4.81+	8.99 ± 6.27+	33.23 ± 10.56+	2.52 ± 4.54+
DZN	55.16 ± 8.90+	6.90 ± 5.55+	7.14 ± 8.29+	29.87 ± 9.45+	0.94 ± 1.45
Cd+DZN	49.29 ± 9.74+	6.76 ± 5.78+	13.28 ± 7.72+	29.41 ± 11.51+	1.27 ± 2.58

\bar{x} – mean, SD – standard deviation, +P<0.05

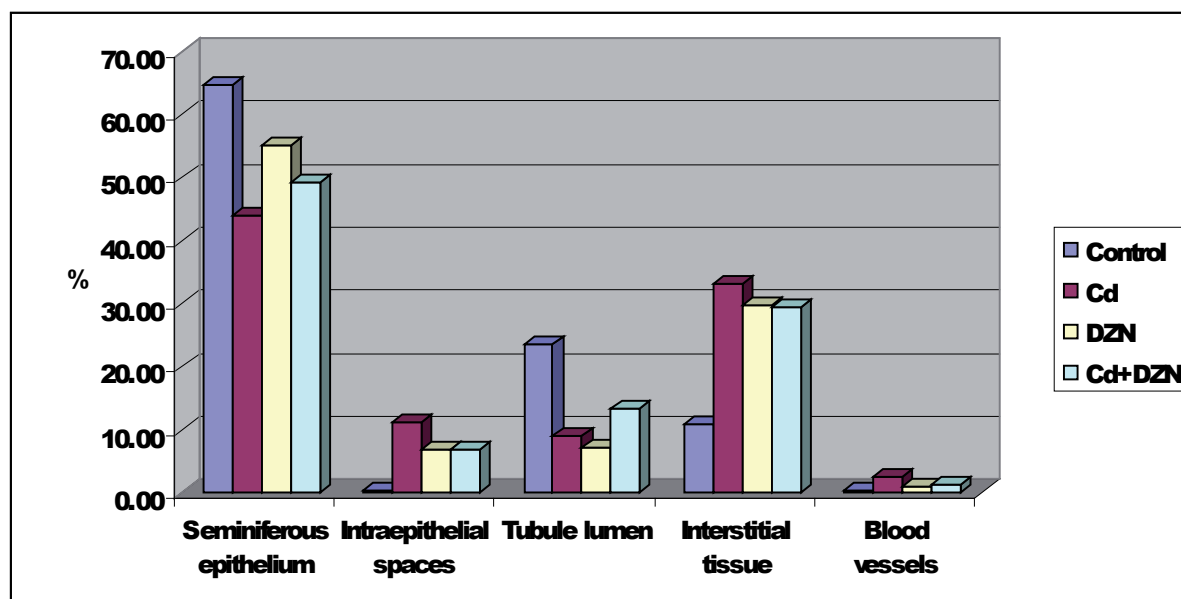
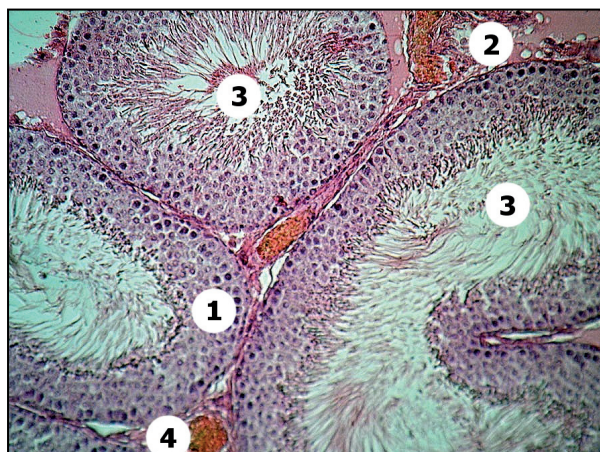


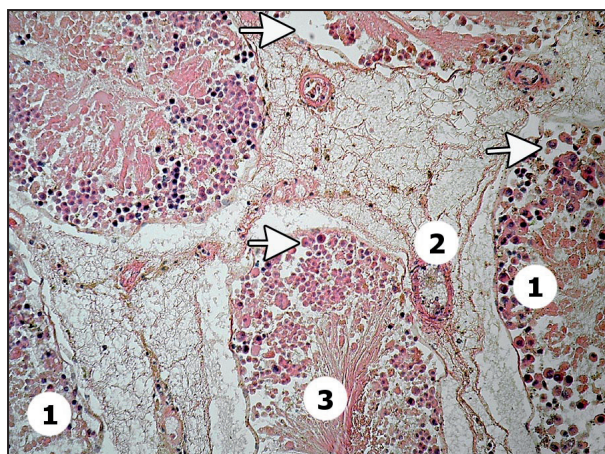
Fig. 1: Relative volumes (%) of the testicular structures in experimental and control animals



1 – seminiferous epithelium with active spermatogenesis, 2 – interstitial connective tissue with Leydig cells, 3 – tubule lumen with spermatozoa, 4 – blood vessel

Fig. 2: Control rat testis (200x, HE)

cadmium exposure (group A), the testes showed injury and atrophy of seminiferous tubules. Many seminiferous tubules contained damaged germinal layer, degeneration and disorganization of the cellular layers (figure 3, 4). Significant occurrence of intraepithelial empty spaces ($P < 0.05$) indicating loss of germ cells has also been found in the group A. The basal lamina was undulated and the spermatogenesis was almost absent. The decreases in testis weight, disruption of blood-testis barrier, edema, necrosis and loss of germ cells have been summarized

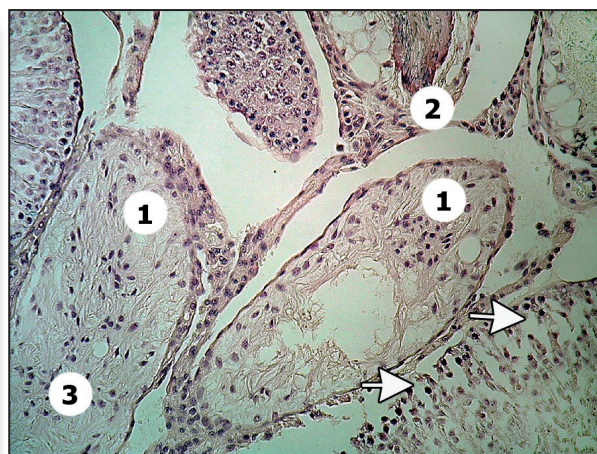


1 - disintegration of seminiferous epithelium, 2 – extended interstitial spaces with dilated blood vessels, 3 – delumination of the tubules, arrows - intraepithelial spaces as a result of released germ cells from epithelium

Fig. 3: Rat testis 36 hours after i.p. cadmium administration (200x, HE)

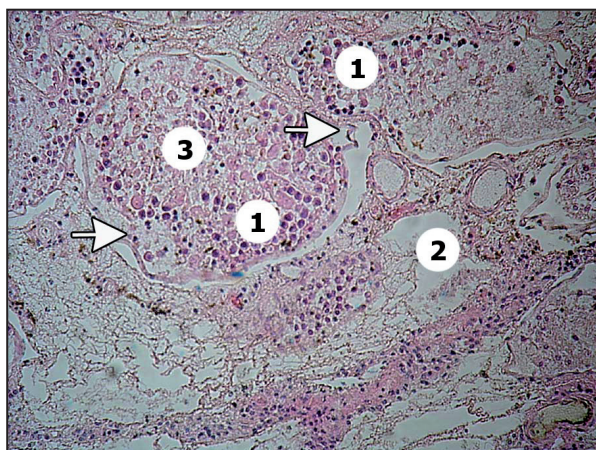
as consequences of cadmium-induced testicular injury (Siu et al., 2009). The morphometric results in our experiment confirmed significant histopathological disorders in seminiferous tubules resulting in tubular degeneration and spermatogenic damage with significant (20.77 %) reduction in epithelial volume and significant (14.59 %) decrease in tubule lumen volume compared to control ($P < 0.05$), accompanied by a 22.30 % increase in the interstitial volume ($P < 0.05$). An extensive changes in the testis showed massive haemorrhagic necrosis, vacuolization and significant dilatation of blood vessels (2.23 % increase, $P < 0.05$) caused by the modification of vascular permeability as an acute effect of cadmium on testicular structure. The results of the present study are in accordance with the results reported earlier by some other authors. Haemorrhage in the interstitium, necrosis and apoptosis in seminiferous tubule epithelium following acute Cd injection have been reported by Bonda et al. (2004). The qualitative analysis of testicular tissues in mouse after i.p. administration of cadmium in single dose (0.25 mg/kg and 0.5 mg/kg b.w.) detected a significant increase in the relative volume of interstitium with dilated blood vessels, undulation of basal membrane and empty spaces in germinal epithelium (Massányi et al., 2008). Toman et al. (2002) have found significant decrease in the relative volume of germinal epithelium (10.64 %) compared to control rabbits and have defined testicular necrosis as a result of ischaemic defect due to direct cadmium effects on vascular system.

Administration of diazinon causes injury of the male rat testes characterized by different degrees of degenerative changes in seminiferous tubules. Significant



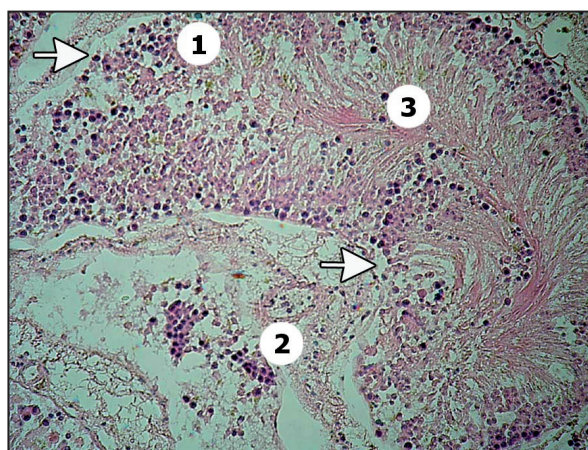
1 - seminiferous epithelium atrophy, 2 – extended interstitial spaces with dilated blood vessels, 3 – delumination of the tubules, arrows - intraepithelial spaces

Fig. 4: Rat testis 36 hours after i.p. cadmium administration (200x, HE)



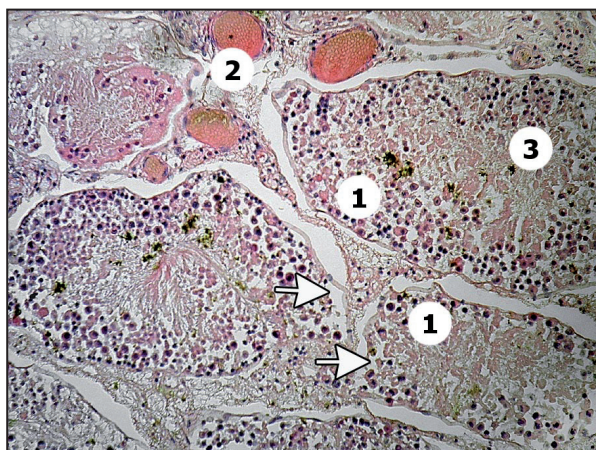
1 – seminiferous epithelium destruction, 2 – widened interstitial spaces with blood vessels, 3 – shrunken atrophied tubule, arrows – intraepithelial spaces, undulated basal lamina

Fig. 5: Rat testis 36 hours after i.p. diazinon administration (200x, HE)



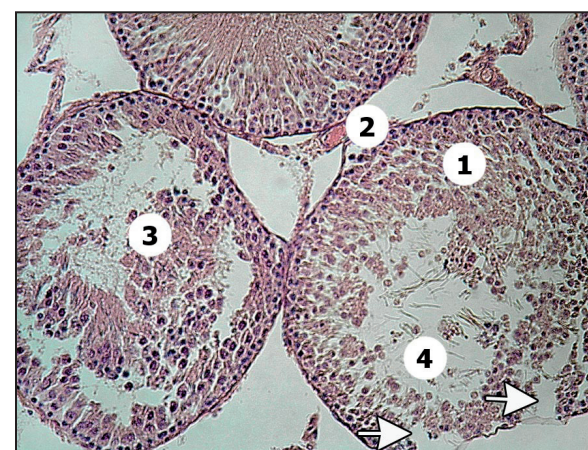
1 – damaged germinal epithelium, 2 – interstitial connective tissue with blood vessel, 3 – lumen filled by degenerated germinal cells, arrows – epithelium vacuolization

Fig. 6: Rat testis 36 hours after i.p. diazinon administration (200x, HE)



1 – degenerative changes in epithelium, 2 – interstitial spaces with dilated blood vessels, 3 – lumen filled by dead germinal cells, arrows – epithelium vacuolization

Fig. 7: Rat testis 36 hours after i.p. cadmium-diazinon administration (200x, HE)



1 – disorganization of the peripheral seminiferous tubules, 2 – interstitial spaces, blood vessels, 3 – lumen filled by germinal cells, 4 – lumen with damaged spermatozoa, arrows – intraepithelial spaces

Fig. 8: Rat testis 36 hours after i.p. cadmium-diazinon administration (200x, HE)

reduction in diameter and weight of testes, decrease in spermatogenic, Leydig and Sertoli cells (Fattahi et al., 2009), damage to the germinal epithelium in the testes leading to the spermatogenesis failure caused by diazinon exposure have been observed (Toman et al., 2009b). In contrast, irregular changes in the diameter of the seminiferous tubules in testis of bluegill depending on time of exposure have been reported by Dutta and Meijer (2003). The increase in the diameter of the seminiferous tubule may be caused by weakening of the surrounding

connective tissue due to exposure to diazinon. In our experiment, in rats treated with diazinon at dose of 20 mg/kg b.w., disrupted structure of the testis was found (figure 5, 6). The seminiferous tubules underwent the atrophy associated with a 9.66 % decrease in the relative volume of seminiferous epithelium, which is in accordance with a decrease in seminiferous epithelium height of mouse testis after a single dose of diazinon, found by Sarabia et al. (2009). The shrunken tubules with the detached germ cells filling the tubular lumen induced significant

delumination ($P < 0.05$) of the tubules. Vacuolization of seminiferous epithelium was significantly higher (6.90 %, $P < 0.05$) in the diazinon-treated group (group B) than that of the control one (0.38 %). Morphometrical data also showed a significant ($P < 0.05$) extension of interstitial tissue volume by 18.94 %. Increased and dilated blood vessels (0.94 %), although with no significant difference compared to the control (0.29 %), were also observed.

Currently, limited information on reproductive effects of cadmium and diazinon by the combined administration are provided. Morphometrical and histopathological data showed that animals, intraperitoneally exposed to cadmium (2 mg/kg b.w.) and diazinon (20 mg/kg b.w.), simultaneously exhibited significant decrease ($P < 0.05$) in relative volume of germinal epithelium and tubule lumen compared to the control. Although both compounds were able to damage significantly the seminiferous epithelium when administered in single doses, the injection of Cd and diazinon at the same time did not pose stronger changes. The relative volume of seminiferous epithelium was higher than that of the group A with a single Cd administration. It is an interesting finding, that cadmium, in combination with diazinon, was not able to damage the testis as extensively as in a single dose. Also, the epithelium vacuolization and interstitium volume were increased only to the levels found in the diazinon-treated group. Changes in the testes of the group C, necrosis in some seminiferous tubules with oedema in the interstitial tissue are shown on the figures 7 and 8. A synergistic or additional effect of acute coexposure to cadmium and diazinon in male rats was supposed, but the results did not confirm these assumptions.

CONCLUSION

Morphometrical data confirmed the histological findings that cadmium and diazinon induce testicular alterations. Degenerative damage was detected as significant decrease in the relative volume of seminiferous epithelium. Loss of germ cells due to disarrangement of cellular layers resulted in a significant increase of intraepithelial spaces simultaneously with the reduction of tubule lumen and enlargement of interstitial tissue. Significant increase in the blood vessel volume in the cadmium-exposed group resulted in oedematous and haemorrhagic widened interstitial tissue. However, the simultaneous administration of cadmium and diazinon had no synergistic or additional effect to the rat testis. Results indicate an adverse effects of environmental and food contaminants on the structure of rats testes and failure of spermatogenesis after an intraperitoneal administration. Therefore, animal study has demonstrated that cadmium and diazinon act as testicular toxicants disrupting male

reproduction and their exposure may pose the risk of fertility disorders in men. Further experimental research is needed, particularly effects on reproduction function after a long-term oral exposure, which may occur by drinking contaminated water or eating foods containing cadmium and diazinon residue.

ACKNOWLEDGEMENT

The authors are grateful for the financial support of the VEGA grant No. 1/0619/10.

REFERENCES

- ATSDR – Agency for toxic substances and disease registry, 2008a. Toxicological profile for cadmium, U. S. Department of health and human services, 2008a, 512. p.
- ATSDR – Agency for toxic substances and disease registry, 2008b. Toxicological profile for diazinon, U. S. Department of health and human services, 2008b, 298. p.
- ATTIA, A. M. – NASR, H. M., 2009. Evaluation of protective effect of omega-3 fatty acids and selenium on paraquat intoxicated rats. *Slovak J. Anim. Sci.*, vol. 42, 2009, p. 180-187.
- BENOFF, S. – JACOB, A. – HURLEY, I. R. 2000. Male infertility and environmental exposure to lead and cadmium. *Human Reprod. Update*, vol. 6, 2000, p. 107-121.
- BONDA, E. – WLOSTOWSKI, T. – KRASOWSKA, A., 2004. Testicular toxicity induced by dietary cadmium is associated with decreased testicular zinc and increased hepatic and renal metallothionein and zinc in the bank vole (*Clethrionomys glareolus*). *BioMetals*, vol. 17, 2004, p. 615-624.
- DUTTA, H. M. – MEIJER, H. J. 2003. Sublethal effects of diazinon on the structure of the testis of bluegill, *Lepomis macrochirus*: a microscopic analysis. *Environ Pollut*, vol. 125, 2003, p. 355-360.
- EI-SHAHAT, A. E. – GABR, A. – MEKI, A. – MEHENA, E. 2009. Altered Testicular Morphology and Oxidative Stress Induced by Cadmium in Experimental Rats and Protective Effect of Simultaneous Green Tea Extract. *Int. J. Morphol.*, vol. 27, 2009, p. 757-764.
- EFSA (European Food Safety Authority Panel on Contaminants in the Food Chain), 2009. Cadmium in food. Scientific opinion of the panel on contaminants in the food chain. *The EFSA Journal*, 2009, 980, p. 1-139.
- FATTAHI, F. – PARIVAR, K. – JORSARAEI, S. G. A. – MOGHADAMNIA, A. A. 2009. The effects of diazinon on testosterone, FSH and LH levels and testicular tissue in mice. *Iran. J. Reprod. Med.*, vol. 7, 2009, p. 59-64.
- FRIED, K. W. – ROZMAN, K. K., 2008. Toxicity of selected chemicals. In: GREIM, H. – SNYDER, R.: *Toxicology and risk assessment: A comprehensive introduction*. Chichester: John Wiley & sons, Ltd., 2008, p. 513-655. ISBN 978-0-470-86893-5.
- GUILLETTE, L. J. Jr. – EDWARDS, T. M., 2008. Environmental influences on fertility: Can we learn lessons from studies of wildlife? *Fertil. Steril.*, vol. 89, 2008, p. 21-24.

- HSIEH, M. L. – HUANG, S. T. – HUANG, H. C. – CHEN, Y. – HSU, Y. C. 2009. The reliability of ultrasonographic measurements for testicular volume assessment: comparison of three common formulas with true testicular volume. *Asian J. Androl.*, vol. 11, 2009, p. 261-265.
- JÄRUP, L. – ÅKESSON, A. 2009. Current status of cadmium as an environmental health problem. *Toxicol. Appl. Pharmacol.*, vol. 3, 2009, p. 201-208.
- KIMÁKOVÁ, T. – KORÉNEKOVÁ, B. – BERNASOVSKÁ, K., 2006. Comparison of effects of cadmium and selenium on renal histological changes in Japanese Quails. In: *Second Central and Eastern Europe Conference on Health and the Environment*. Bratislava, 2006, s. 36.
- LATENDRESSE, J. R. – WARBRITTON, A. R. – JONASSEN, H. – CREASY, D. M. 2002. Fixation of testes and eyes using a modified Davidson's fluid: comparison with Bouin's fluid and conventional Davidson's fluid, *Toxicol. Pathol.*, vol. 30, 2002, p. 524-533.
- LUKÁČ, N. – MASSÁNYI, P. – KROČKOVÁ, J. – NAĎ, P. – SLAMEČKA, J. – ONDRUŠKA, L. – FORMICKI, G. – TRANDŽÍK, J. 2009. Relationship between trace element concentrations and spermatozoa quality in rabbit semen. *Slovak J. Anim. Sci.*, vol. 42, 2009, Supplement 1, p. 46-50.
- MASSÁNYI, P. – LUKÁČ, N. – KOVÁČIK, J. – TOMAN, R. – STAWARZ, R. – CIGÁNKOVÁ, V. – CIAGLO, A. 2008. Heavy metals effects on testicular structure in vivo: Abstracts from the 8th international conference on risk factors of food chain, Krakow, *Slovak J. Anim. Sci.*, vol. 41, 2008, p. 208.
- OLSSON, I. M. – BENSRYD I. – LUNDH T. – OTTOSSON, H. – SKERFVING S. – OSKARSSON, A. 2002. Cadmium in blood and urine impact of sex, age, dietary intake, iron status, and former smoking association of renal effects. *Environ. Health Perspect.*, vol. 110, 2002, p. 1185-1190.
- PIÑA-GUZMÁN, B. – SOLÍS-HEREDIA, M. J. – QUINTANILLA-VEGA, B. 2005. Diazinon alters sperm chromatin structure in mice by phosphorylating nuclear protamines. *Toxicol. Appl. Pharmacol.*, vol. 202, 2005, p. 189-198.
- SANTOS, F. W. – ORO, T. – ZENI, G. – ROCHA, J. B. T. – DO NASCIMENTO, P. C. – NOGUEIRA, C. W. 2004. Cadmium induced testicular damage and its response to administration of succimer and diphenyl diselenide in mice. *Toxicol. Lett.*, vol. 152, 2004, p. 255-263.
- SARABIA, L. – MAUER, I. – BUSTOS-OBREGÓN, E. 2009. Melatonin prevents damage elicited by the organophosphorus pesticide diazinon on the mouse testis. *Ecotox. Environ. Safety*, vol. 72, 2009, p. 938-942.
- SIU, E. R. – MRUK, D. D. – PORTO, C. S. – YAN CHENG, C. 2009. Cadmium-induced testicular injury. *Toxicol. Appl. Pharmacol.*, vol. 3, 2009, p. 240-249.
- SCHUMACHER, M. – CAMP, S. – MAULET, Y. et al. 1986. Primary structure of Torpedo californica acetylcholinesterase deduced from its cDNA sequence. *Nature*, vol. 319, 1986, p. 407-409.
- TANG, J. – ZHANG, M. – CHENG, G. – LU, Y. 2009. Diazinon Determination Using High Performance Liquid Chromatography: A Comparison of the ENVI-Carb Column with the Immunoaffinity Column for the Pretreatment of Water and Soil Samples, *Bull. Environ. Contam. Toxicol.*, vol. 83, 2009, p. 626-629.
- THOMPSON, J. – BANNIGAN, J. 2008. Cadmium: Toxic effects on the reproductive system and the embryo. *Reprod. Toxicol.*, vol. 25, 2008, p. 304-15.
- TOMAN, R. – MASSÁNYI, P. 2002. Changes in the testis and epididymis of rabbits after an intraperitoneal and peroral administration of cadmium. *Trace Elem. Electrolytes*, vol. 19, 2002, p. 114-117.
- TOMAN, R. – GOLIAN, J. – ŠIŠKA, B. – MASSÁNYI, P. – LUKÁČ, P. – ADAMKOVIČOVÁ, M. 2009a. Cadmium and selenium in animal tissues and their interactions after an experimental administration to rats. *Slovak J. Anim. Sci.*, vol. 42, 2009a, Supplement 1, p. 115-118.
- TOMAN, R. – HLUCHÝ, S. – ŠIŠKA, B. – CABAJ, M. – GOLIAN, J. – MASSÁNYI, P. – LUKÁČ, N. 2009b. Structural changes in the rat testes caused by diazinon administration, *Lucrări științifice Zootehnie și Biotehnologii*, vol. 42, 2009b, p. 295-299.
- TREMELLEN, K. 2008. Oxidative stress and male infertility – a clinical perspectives. *Hum. Reprod. Update*, vol. 14, 2008, p. 243-258.
- TURNER, T. T. – LYSIAK, J. J. 2008. Oxidative stress: a common factor in testicular dysfunction. *J. Androl.*, vol. 29, 2008, p. 488-498.
- WOODRUFF, T. J. – CARLSON, A. – SCWARTZ, J. M. – GIUDICE, L. C. 2008. Proceedings of the Summit on Environmental Challenges to Reproductive Health and Fertility: Executive Summary. *Fertil. Steril.*, vol. 89, 2008, p. 281-300.