

Scientific paper formerly presented

## VARIABILITY IN ORIGIN OF SOME BRANCHES OF *AORTA THORACICA* IN RABBIT

D. MAŽENSKÝ<sup>1\*</sup>, K. VDOVIAKOVÁ<sup>1</sup>, E. PETROVOVÁ<sup>1</sup>, L. LUPTÁKOVÁ<sup>2</sup>

<sup>1</sup>Department of Anatomy, Histology and Physiology, University of Veterinary Medicine, Košice, Slovak Republic

<sup>2</sup>Department of Biology and Genetics, University of Veterinary Medicine, Košice, Slovak Republic

---

### ABSTRACT

The study investigated anatomical variations in the origin of some branches of *aorta thoracica*. It was carried out on thirty adult rabbits of both sexes. We prepared corrosive casts of the arterial system using Duracryl Dental®. They showed irregular origin of bilateral *arteriae intercostales dorsales*. Our results allowed us to state the following: in 63 % of cases the left *arteriae intercostales dorsales* originated more cranially than the right ones and in 20 % they originated at the same level from *aorta thoracica*. In 7 % of cases we observed that in the cranial section the right *arteriae intercostales dorsales* arose more cranially than the left ones and starting from the level of the ninth thoracic vertebra the left *arteriae intercostales dorsales* originated more cranially than the right ones. The origin of these arteries converged in the caudal direction. The present study was conducted in order to complete the picture of arterial supply of the dorsal thorax which complements the rabbit spinal blood supply.

**Key words:** arteries; corrosive casts; origin; variability

---

### INTRODUCTION

Laboratory animals have been a direct object of a great number of experiments that cannot be carried out *in vitro*. A number of authors paid attention to body structure and organ systems (Barone et al., 1973; Cooper, 1973; Hebel and Stromberg, 1976; Mc Laughlin, 1972; Popesko et al., 1992; Smallwood, 1992) but some papers described also various details (Rajtová and Danko, 2001).

Anatomical studies, including those dealing with spine blood supply of domestic animals, are closely related to spine traumatic damage. Experiments conducted

on laboratory animals provided at varying extent the knowledge which can be applied to domestic animals but also to humans. As an example, we can mention the study of partial or total ischaemia of the spinal cord, effects of some drugs on the nervous system and also of various experimental surgical interventions and pathological mechanisms (Čížková et al., 2001).

As far as laboratory animals are concerned, the branches of *aorta descendens* in rats attracted the greatest attention (Hebel and Stromberg, 1976; Popesko et al., 1992).

The aim of the present study was to investigate the arrangement of origin of *arteriae intercostales dorsales*.

---

\*Correspondence: E-mail: mazenskyd@azet.sk

MVDr. Dávid Maženský, Department of Anatomy, Histology and Physiology,  
University of Veterinary Medicine, Komenského 73, 041 81 Košice, Slovak Republic  
Tel.: + 421 915 984 686 Fax: + 421 055 298 10 11

## MATERIAL AND METHODS

The study was carried out on thirty adult rabbits with the same proportion of both sexes. The animals were kept in experimental quarters and were supplied with feed and water *ad libitum*. They were euthanized by prolonged anaesthesia induced by aether. Subsequently, the arterial network was flushed with saline solution. Before flushing we opened the right atrium in order to decrease the pressure and ensure good injection. We used Duracryl Dental® (Flešárová et al., 2003) as an injection medium. Maceration was carried out in 2 - 4 % KOH for 2 days.

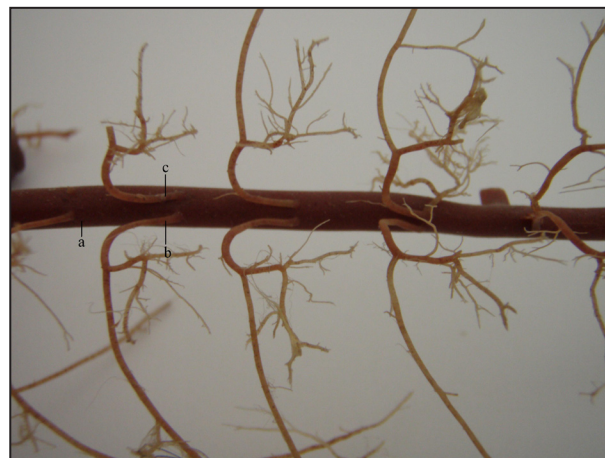
The latest veterinary anatomical nomenclature was used throughout the study.

## RESULTS

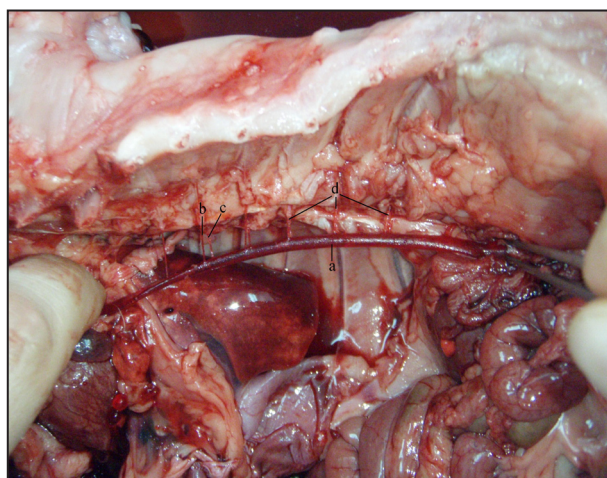
Vascularisation of the thoracic part of the spinal cord is ensured by *rami spinales* from *arteriae intercostales dorsales*. *Arteriae intercostales dorsales* and *arteriae lumbales* form separate branches of the *aorta thoracica* and are paired.

In all cases observed, the origin of *arteriae intercostales dorsales* converged in the caudal direction. In 63 % of cases the left *arteriae intercostales dorsales* originated more cranially than the right ones. In 20 % of cases the right and left *arteriae intercostales dorsales* originated from *aorta thoracica* at the same level. In 10 % the cranial *arteriae intercostales dorsales* originated

at the same level, and starting from the 9 - 12 thoracic vertebrae, the left arteries originated from *aorta thoracica* more cranially than the right ones (Fig. 1). In 7 % of cases we observed that in the cranial section the right *arteriae intercostales dorsales* arose more cranially than the left ones and starting from the level of the ninth thoracic vertebra the left *arteriae intercostales dorsales* originated more cranially than the right ones (Fig. 2).



**Fig. 2:** Corrosive cast of *aorta thoracica* with some of its branches. Dorsal view:  
**a** – *aorta abdominalis*,  
**b** – *a. intercostalis dorsalis sinistra*,  
**c** – *a. intercostalis dorsalis dextra*



**Fig. 1:** Ceiling of the thoracic cavity with *aorta thoracica* and some of its branches:  
**a** – *aorta thoracica*,  
**b** – *aa. intercostales dorsales sinistrae*,  
**c** – *aa. intercostales dorsales dextrae*,  
**d** – *arteriae intercostales dorsales originating at the same level*

The origin of bilateral arteries converged caudally and the point of origin of these arteries acquired the shapes V or Y in 93 % of cases. In the remaining 7 % the right and left *arteriae intercostales dorsales* originated independently at equal spacing.

Generally, 60 % of all variations, observed in our study, occurred in males and the remaining 40 % were detected in females.

## DISCUSSION

Similar to other species of farm animals, the blood supply to the thoracic section of rabbit spinal cord occurs through *arteriae intercostales dorsales*. The origin of these arteries branching off from the aorta of laboratory animals varies in dependence on species. The first four intercostal spaces in rabbits are supplied with blood by *arteriae intercostales dorsales*, which branch off from *arteria intercostalis suprema*, first five in guinea pigs, first two in rabbit and first three in mouse and hamster. *Rami spinales*, which supply the spinal cord, originate from these arteries. These arteries pass through *foramina*

*intervertabralia* (Popesko et al., 1992). The remaining portion of thoracic spinal cord is supplied by *arteriae intercostales dorsales*, the branches of *aorta thoracica*. Mice and hamsters have nine *arteriae intercostales dorsales*, rabbits and hamsters seven (Popesko et al., 1992) and rats eight (Hebel and Stromberg, 1989). According to our observations, *arteriae intercostales dorsales* originated irregularly from *aorta thoracica*. Only in 20 % of cases they originated from *aorta thoracica* at the same level. In the majority of corrosive casts the left *arteriae intercostales dorsales* originated more cranially than the right ones. The places of origin of these bilateral arteries converged caudally and in these places they acquired V shape.

## CONCLUSION

Our study indicates the need to request for detailed knowledge about blood supply in laboratory animals. This will contribute to obtaining more objective results when carrying countless experiments on laboratory animals.

## REFERENCES

- BARONE, R.– PAVAU, C. – BLIN, P.C. – CUQ, P. 1973. *Atlas d'Anatomie du Lapin*. Paris: Masson E., CEditions, 1973, p. 203. ISBN 1271534
- COOPER, G. – SCHILLER, A. L. 1975. *Anatomy of the Guinea-Pig*. Massachusetts: Harvard University Press, 1973, p. 403. ISBN 0-674-03159-8
- ČÍŽKOVÁ, D. – KAFKA, J. – ČÍŽEK, M. – ŠEVČÍK, A. – MARŠALA, J. 2001. The cauda equina syndrome induces synthesis of stress proteins. In: *Psychiatry*, vol. 5, 2001, p. 15-16.
- FLEŠÁROVÁ, S. – TEFAYE, A. – DANKO, J. – BÁTOR, R. – DORKO, F. – BARTA, A. 2003. Morphological variations of arcus aortae in rabbits. *Acta Veterinaria Brno*. vol.72, Supplementum, 2003, p. 20.
- HEBEL, R. – STROMBERG, M. W. 1976. *Anatomy of the Laboratory Rat*. Baltimore: Williams and Wilkins, 1976, p. 106. ISBN 3343023019
- HEBEL, R. – STROMBERG, M. W. 1989. *Anatomy and Embryology of the Laboratory Rat*. Wörthsee : BioMed Verlag, 1989, p. 97-112. ISBN 3-9801234-0-5
- MC LAUGHLIN, CH.A. 1972. *Laboratory Anatomy of the Rabbit*. Dubuque, Iowa : W. M. C. Brown Co. Publishers, 1972, p. 112. ISBN 978-0-697-04931-5
- POPESKO, P. – RAJTOVÁ, V. – HORÁK, J. 1992. *A colour Atlas of Anatomy of Small Laboratory Animals*, Vol. I., London : Wolfe Publishing Ltd., 1992, p. 255. ISBN 978-0-7020-2699-7
- RAJTOVÁ, V. – DANKO, J. 2001. Vasculature of the testis, epididymidis and ductus deferens of rabbit. The Arteries. *Acta Veterinaria Brno*, vol. 70, 2001, p. 3-7.
- SMALWOOD, J. E. 1992. *A Guided Tour of Veterinary Anatomy*. Philadelphia, London, Tokyo: W. B. Saunders Company, 1992, p. 367. ISBN 0721637310