

INFLUENCE OF *IN OVO* ADMINISTRATION OF OYSTER MUSHROOM EXTRACT ON MORPHOLOGICAL AND HISTOLOGICAL CHARACTERISTICS OF INTESTINES OF BROILER CHICKENS

Oluwademilade DAINI^{1*}, Olajide SOGUNLE¹, Ayotunde ADEBAMBO², Kamorudeen SAFIYU³, Olusola ODUTAYO¹, Oluwabusayo IRIVBOJE⁴

¹Department of Animal Production and Health, Federal University of Agriculture, Abeokuta, P.M.B. 22240, Ogun State, Nigeria

²Department of Animal Breeding and Genetics, Federal University of Agriculture, Abeokuta, P.M.B. 22240, Ogun State, Nigeria

³Department of Animal Production and Livestock Management, Michael Okpara University of Agriculture, Umudike, Abia State, Nigeria

⁴Agricultural Technology Department, The Federal Polytechnic, Ilaro, P.M.B 50, Ogun State, Nigeria

ABSTRACT

This study investigated the influence of *in ovo* administration of oyster mushroom aqueous extract on intestinal development of broiler chickens. A total of 600 hatching eggs of Arbor acre strain of broiler chickens were used in this experiment. The eggs were divided into three treatments; T1: Control (non-injected eggs), T2: *in ovo* administration of 0.1 ml of oyster mushroom aqueous extract and T3: *in ovo* administration of 0.2 ml of oyster mushroom aqueous extract. *In ovo* injection of eggs was carried out on the 18th day of incubation and hatched chicks were brooded for 2 weeks and the experiment lasted for six weeks. At the starter and finisher (7th and 56th days of age) phases, two birds per replicate were randomly selected for intestinal evaluation. Data collected were subjected to Analysis of Variance using General Linear Model. Results from the starter phase showed jejunal villus height significantly ($p < 0.05$) ranged from 290.62 μm in birds in T1 to 415.60 μm in birds in the T3 group. Moreover, jejunal crypt depth ranged from 51.96 μm to 115.62 μm , while muscular wall thickness ranged from 53.94 μm to 139.23 μm with the highest recorded in the T2 birds. In finisher broilers, there was significant ($p < 0.05$) difference among treatments for duodenum length, muscular wall thickness of the ileum and colon length. Histological plates taken in the starter phase indicated no visible lesion in the villi across treatments with crypts appearing normal. However, finisher broilers in the T2 group had preeminent villi representation showing intact enterocytes and slightly high and more prominent crypts. Therefore, to improve jejunal morphology in the starter phase as well as increased intestinal length and superior duodenal histology in the finisher phase of broiler chickens, *in ovo* administration of 0.1 ml oyster mushroom aqueous extract is recommended.

Key words: *in ovo* injection; oyster mushroom; intestinal morphology; intestinal histology; broiler chickens

INTRODUCTION

Broiler chicks experience delayed intake of water and feeds at hatch, which is sometimes more than 36 h due to hatchery operations such as vent-sexing and vaccination, as well as chick transportation (Obun and Osaguona, 2013). This delay has been reported by researchers (Noy *et al.*, 2001; Gonzales *et al.*,

2003; Latour *et al.*, 2003) to negatively impact post-hatch performance along with increased mortality (Willemsen *et al.*, 2010). Thus, early feeding strategies including *in ovo* feeding have been developed to possibly reverse the negative effects of delayed feeding (Uni and Ferket, 2004; Leeson, 2008). The basic laboratory concept of *in ovo* technique was initially used for vaccination against Marek's disease (Fabio,

Copyright: © 2024 Daini et al.

***Correspondence:** E-mail: dainidemi@gmail.com

Oluwademilade Daini, Department of Animal Production and Health, Federal University of Agriculture, Abeokuta, P.M.B. 22240, Ogun State, Nigeria
Tel.: +2348163545198

Received: January 18, 2024

Accepted: March 8, 2024



2008). It involves punching a small hole through the eggshell into the air cell of the egg to deliver nutrients and/or drugs for the developing embryo through the hole on day 18 of the bird's 21-day incubation period (Sogunle *et al.*, 2021). Previous researchers (Salmanzadeh *et al.*, 2011; Hadi *et al.*, 2014; Sogunle *et al.*, 2018) have also confirmed the viability of *in ovo* administration of vaccines, vitamins, amino acids, minerals and drugs such as antibiotics to improve poultry production indices. Consequently, due to the occurrence of drug residues in edible poultry tissues (meat and eggs) and the frequent exposure to low levels of antibiotics can cause resistance through mutation (Olatoye and Ehinmowo, 2009; Shareef *et al.*, 2009), safe alternatives to antibiotic such as natural products and phytobiotics have been investigated (Sogunle *et al.*, 2017).

One of such natural products is Oyster mushroom (*Pleurotus ostreatus*), which is known to have antioxidant and immunomodulatory properties (Elmastas *et al.*, 2007; Salmanzadeh, 2012; Sogunle *et al.*, 2021). It has been shown to improve growth, immunity and intestinal health of broiler chickens (Guo *et al.*, 2004; Machado *et al.*, 2007; Giannenas *et al.*, 2010). Substances such as polysaccharides, glycosides, alkaloids, volatile oils and organic acids, present in mushrooms, are responsible for regulating the immune responses (Yang and Feng, 1998; Willis *et al.*, 2007). Mushrooms have also been reported to possess hepatoprotective properties to combat aflatoxin-induced hepatotoxicity in broiler chickens (Yogeswari *et al.*, 2012). According to Sogunle *et al.* (2019), oyster mushroom supplementation improved packed cell volume and haemoglobin concentration in cockerels. Although the substitution of antibiotics with plant extracts is not a new practice in the poultry industry, however, the role of *in ovo* administration of oyster mushroom aqueous extract on intestinal health of broiler chickens is yet to be investigated. The intestine is an important organ responsible for the digestion and absorption of nutrients. Therefore, intestinal development and maturation are known to play a major role in promoting growth of the newly hatched chick and to have a long-term effect on broiler performance (Uni *et al.*, 1999; Sklan, 2001; Dibner and Richards, 2005). In addition, some natural additives have been found to improve intestinal morpho-physiology (Wang *et al.*, 2007; Eyng *et al.*, 2014; Fazayeli-Rad *et al.*, 2015; Chegini *et al.*, 2018). This study aimed to investigate the influence of

in ovo administration of oyster mushroom extract on morphological and histological characteristics of intestines of broiler chickens.

MATERIAL AND METHODS

Experimental site

The incubation aspect of this study was carried out at the Hatchery Unit of the College of Animal Science and Livestock Production, Federal University of Agriculture, Abeokuta, Ogun State, Nigeria. Hatched chicks rearing was carried out at the Poultry Unit of the Directorate of University Farms (DUFARMS), Federal University of Agriculture, Abeokuta, Ogun State, Nigeria. Intestinal sampling was carried out at the Veterinary Pathology Laboratory of the same institution. The site is located in the rain forest vegetation zone of South-Western Nigeria at latitude 7° 13' N and longitude 3° 26' E on an altitude of 127 m (Google Map, 2019).

Management and incubation of fertile eggs

A total of 600 fertile eggs of Arbor acre broiler strain were purchased from a reputable breeder in Ibadan, Oyo state. The fertile eggs were sorted and balanced for weight. Thereafter, the eggs were fumigated using KMnO₄ and formaldehyde at the ratio of 2:1 for 20 minutes in an enclosed chamber before setting. Incubation was done at the temperature of 37.50 °C and 37.00 °C, relative humidity of 50 % and candling was done on the 14th day. After candling, 336 eggs (56 % fertility) were ascertained to contain viable embryos. These eggs were distributed into three groups: (T1: Control (non-injected eggs)), (T2: 0.1 ml oyster mushroom injection group) and (T3: 0.2 ml oyster mushroom injection group) each containing 112 eggs.

Preparation and *in ovo* administration of oyster mushroom (*Pleurotus ostreatus*) extract

Fresh oyster mushrooms (*Pleurotus ostreatus*) were purchased from a reputable market in Oyo state, Nigeria. The mushrooms were properly rinsed to remove any form of dirt on it. After cleaning, hot water extraction procedure was used for mushroom extraction; where 500 g of oyster mushroom per 1 litre of water were cooked at 57.2 °C for twenty (20) minutes as enunciated by Sogunle *et al.* (2021). The newly formed extracts were then cooled and strain-off the mushrooms with a sieve. Serial dilution was

done to obtain 20 % oyster mushroom extract (i.e. 20 ml of oyster mushroom extract in 80 ml of distilled water). The newly formed solution was kept in a dark-coloured recipient (to prevent photolysis due to light penetration) and then stored in the refrigerator at -4 °C until needed. On the 18th day of embryonic development, the eggs were injected with the oyster mushroom extract using a 24-gauge hypodermic needle, as described by Bhanja *et al.*, (2004). The surface of the broad end of the eggs was sterilized with 30 % ethanol. Afterwards, the injected sites on the eggs were sealed with wax and the eggs transferred to the hatching compartment.

Post-hatch management of birds

A total of 66 chicks were hatched in T1 (58 % hatchability), 59 chicks in T2 (52 % hatchability) and 56 chicks in T3 (50 % hatchability) groups. Birds after hatching still remained in the treatment and they were further divided into five replicates. After hatching, the chicks were brooded for two weeks and reared for six weeks. Commercial broiler diet and drinking water were provided *ad libitum* throughout the entire rearing period of 8 weeks.

Evaluation of intestinal histomorphology

On the 7th and 56th days of the experiment, two birds per replicate were weighed before being sacrificed through cervical dislocation for collection of intestinal portions. The lengths of each of the section of both the small intestine (i.e. duodenum, ileum and jejunum) and large intestine (i.e. caeca and colon) were measured with a meter rule and expressed in cm/100 g live weight according to the procedure described by Odutayo *et al.* (2021). Furthermore, portions of the small intestines from carcasses of each treatment were dehydrated, cleared and embedded into 10 % formalin (100 ml formalin, 900 ml distilled water). Later, segments (1 cm) of the duodenum, ileum and jejunum were placed onto a glass slide, fixed in a wax ribbon and stained with haematoxylin-eosin. Slides were analysed under a microscope and pictures were taken. The images were analysed using the Image J, 1.50i software, as described by Baurhoo *et al.* (2007), to measure the villus height, villus width, crypt depth and muscular wall thickness.

Statistical Analysis

All data collected in this study were subjected to one-way Analysis of Variance (ANOVA) using General

Linear Model, as contained in the Minitab software Version 17.1.0. Significantly ($P < 0.05$) different means among variables were separated using a Tukey test contained in the same software. The model of the study is as follows:

$$Y_{ij} = \mu + T_i + \Sigma_{ij}$$

Where: Y_{ij} = Individual Observation, μ = Overall Mean, T_i = Treatment Effect (*in ovo* injection of Oyster Mushroom extract), Σ_{ij} = Experimental error.

RESULTS AND DISCUSSION

Effect of *in ovo* administration of oyster mushroom (*Pleurotus ostreatus*) aqueous extract on intestinal morphology of broiler chickens at starter phase

As Table 1 shows, there were no significant differences ($p > 0.05$) among all parameters measured except the villus height, crypt depth, and muscular wall thickness of the jejunum. The non-significance in duodenal and ilea measurements in starter broilers, in this study, is contradictory to the report by Uni *et al.* (1999), who observed rapid increase in the intestinal development of pullets after *in ovo* administration. On the other hand, jejunal villus height significantly ($p < 0.05$) ranged from 290.62 μm in T1 birds to 415.60 μm in T3 birds. This may be explained that the bioactive compounds present in oyster mushroom were responsible for the observed increased jejunal villus height observed. According to Wang *et al.* (2020), increased villus height is a precursor of improved growth in piglets as it helps in the stimulation of gastrointestinal tract secretions as well as nutrient digestion and absorption. The results are consistent with the earlier report by Tekeli *et al.* (2010), who revealed that plant extracts (ginger and propolis) both separately and in combination, significantly increased in the length of the intestinal villi of the jejunum in chickens, when compared to the control group. Similarly, Gilani *et al.* (2021) observed increased villus height in broiler chickens in phytobiotic groups. Moreover, jejunal crypt depth ranged from 51.96 to 115.62 μm , while muscular wall thickness ranged from 53.94 to 139.23 μm with the highest recorded in the T2 birds. These results collaborate earlier report of Soltani *et al.* (2019), who observed increased jejunal morphometry parameters in broilers administered phytobiotics *in ovo*.

Table 1. Effect of *in ovo* administration of oyster mushroom (*Pleurotus ostreatus*) aqueous extract on intestinal development of broiler chickens at starter phase

Parameters	<i>In ovo</i> administration of oyster mushroom				<i>P</i> -Value
	T1	T2	T3	SEM	
Live Weight (g)	53.50	57.50	52.50	3.29	0.87
<i>Duodenum</i>					
Length (cm/100 g)	22.17	22.31	22.71	0.61	0.95
Villus Height (µm)	384.56	342.02	261.56	54.24	0.93
Villus Width (µm)	40.82	63.00	50.75	6.26	0.47
Crypt Depth (µm)	39.93	63.79	51.84	7.59	0.50
Muscular Wall Thickness (µm)	78.04	93.31	91.66	11.16	0.73
<i>Ileum</i>					
Length (cm/100 g)	42.56	46.48	50.60	3.56	0.75
Villus Height (µm)	581.44	381.45	522.43	43.04	0.52
Villus Width (µm)	68.35	70.38	83.60	4.00	0.48
Crypt Depth (µm)	71.10	83.04	115.82	9.91	0.45
Muscular Wall Thickness (µm)	111.97	137.23	146.77	8.81	0.46
<i>Jejunum</i>					
Length (cm/100 g)	48.60	44.83	50.02	2.26	0.73
Villus Height (µm)	290.62 ^c	351.57 ^b	415.60 ^a	37.39	0.01
Villus Width (µm)	45.65	68.73	59.16	7.25	0.51
Crypt Depth (µm)	51.96 ^a	115.62 ^a	57.92 ^b	13.83	0.01
Muscular Wall Thickness (µm)	53.94 ^b	139.23 ^a	68.61 ^b	17.62	0.08
<i>Large intestine</i>					
Caecum length (cm/100 g)	18.03	15.85	16.82	0.96	0.75
Colon length (cm/100 g)	5.88	3.91	5.18	0.67	0.59

^{abc}Means in the same row with different superscripts differ significantly ($P < 0.05$); T1: 0 ml of Oyster mushroom extract, T2: 0.1 ml of Oyster mushroom extract, T3: 0.2 ml of Oyster mushroom extract, SEM = Standard Error of Means

Effect of *in ovo* administration of oyster mushroom (*Pleurotus ostreatus*) aqueous extract on intestinal morphology of broiler chickens at finisher phase

As Table 2 shows, there was significant ($p < 0.05$) difference among treatments for duodenum length, muscular wall thickness of the ileum and colon length. This result is in correlation with the data of Soltani *et al.* (2019), who reported increase in duodenal parameters of broiler chickens after *in ovo* administration of an organic substance. Bohorquez *et al.* (2011) also recorded significant increase in the length of the duodenum at finisher phase after *in ovo* vitamin administration. These authors reported that *in ovo* administration of vitamins improved the duodenum parameters and secretion of intestinal mucus and speeded up the maturation of villus epithelial. In addition, the highest value (248.73 µm)

of the muscular wall thickness of the ileum was recorded in birds supplemented with 0.1 ml of the oyster mushroom extract. According to Sadler (2003), oyster mushroom, which contains thiamin, riboflavin, niacin and folic acid, improved morphological indices in birds in oyster mushroom groups. This may be due to the presence of vitamin B groups and vitamin C (antioxidant) in oyster mushroom.

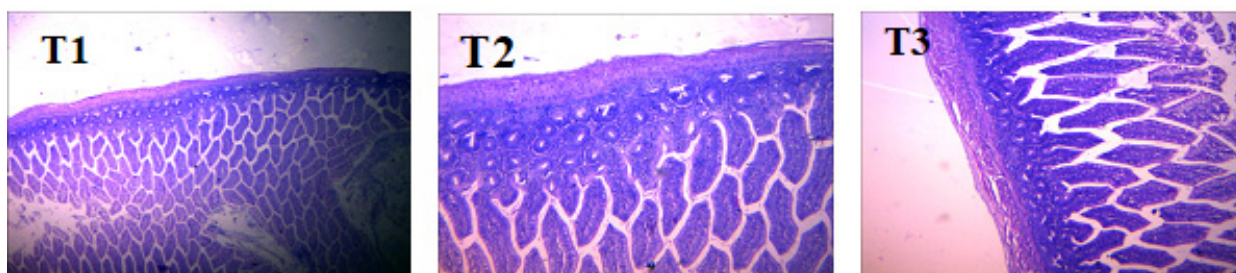
Effect of *in ovo* injection of oyster mushroom (*Pleurotus ostreatus*) aqueous extract on duodenal histology of broiler chickens at starter phase

As it can be shown on Figure 1, no visible lesions were observed in the villi of the small intestine among treatments; the crypts were prominent and appeared normal. The results of the present study support the report by Subramaniyan *et al.* (2019), who reported

Table 2. Effect of *in ovo* administration of oyster mushroom (*Pleurotus ostreatus*) aqueous extract on intestinal morphology of broiler chickens at finisher phase

Parameters	<i>In ovo</i> administration of oyster mushroom				<i>P</i> -Value
	T1	T2	T3	SEM	
Live Weight (g)	1545.5	1690.0	1840.0	210	0.65
<i>Duodenum</i>					
Length (cm/100 g)	2.35 ^{ab}	2.60 ^a	1.72 ^b	0.13	0.03
Villus Height (µm)	1294.09	1233.95	1470.90	104	0.37
Villus Width (µm)	112.879	100.79	84.97	19.3	0.63
Crypt Depth (µm)	137.98	162.50	112.87	18.8	0.31
Muscular Wall Thickness (µm)	175.24	186.26	157.31	30.4	0.80
<i>Ileum</i>					
Length (cm/100 g)	6.23	5.67	5.24	0.24	0.13
Villus Height (µm)	987.01	649.53	1092.39	188	0.35
Villus Width (µm)	123.45	92.74	106.34	15.2	0.45
Crypt Depth (µm)	146.71	133.70	113.18	30.7	0.75
Muscular Wall Thickness (µm)	228.17 ^{ab}	248.73 ^a	158.69 ^b	12.2	0.02
<i>Jejunum</i>					
Length (cm/100 g)	5.782	5.58	4.68	0.46	0.33
Villus Height (µm)	914.86	1112.52	936.98	189	0.74
Villus Width (µm)	113.79	233.37	87.31	72.6	0.42
Crypt Depth (µm)	103.68	144.05	68.75	28.1	0.30
Muscular Wall Thickness (µm)	244.79	167.76	149.31	35.4	0.28
<i>Large intestine</i>					
Caeca length (cm/100 g)	2.73	2.30	2.20	0.23	0.36
Colon length (cm/100 g)	0.61 ^a	0.41 ^b	0.61 ^a	0.01	0.02

^{ab}Means in the same row with different superscripts differ significantly ($P < 0.05$); T1: 0 ml of Oyster mushroom extract, T2: 0.1 ml of Oyster mushroom extract, T3: 0.2 ml of Oyster mushroom extract, SEM = Standard Error of Means

**Figure 1. Effect of *in ovo* administration of oyster mushroom (*Pleurotus ostreatus*) aqueous extract on duodenal histology of broiler chickens at starter phase**

T1: 0 ml of Oyster mushroom extract, T2: 0.1 ml of Oyster mushroom extract, T3: 0.2 ml of Oyster mushroom extract

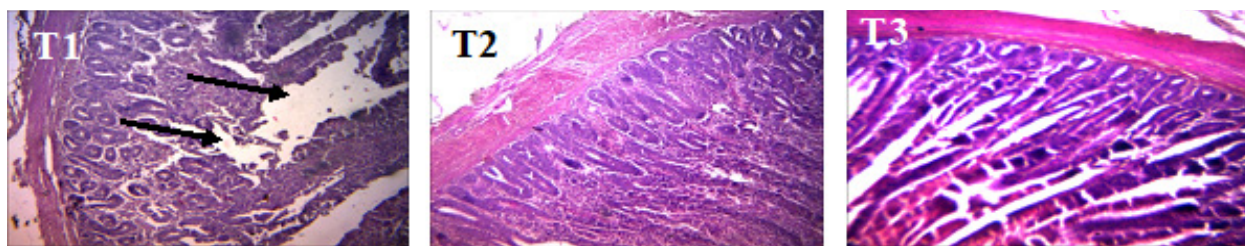


Figure 2. Effect of *in ovo* administration of oyster mushroom (*Pleurotus ostreatus*) aqueous extract on duodenal histology of broiler chickens at finisher phase

T1: 0 ml of Oyster mushroom extract, T2: 0.1 ml of Oyster mushroom extract, T3: 0.2 ml of Oyster mushroom extract

that *in ovo* injection contributed to better tissue representation and prevented lesions in the tissue. The results also proved that oyster mushroom does not contain any toxic substances that can be detrimental to the intestinal tissues of broiler chickens at starter phase.

Effect of *in ovo* injection of oyster mushroom (*Pleurotus ostreatus*) aqueous extract on duodenal histology of broiler chickens at finisher phase

Figure 2 shows positive impact of oyster mushroom on intestinal health of broilers with no lesions observed in the duodenal histology in T2 and T3 groups, while visible lesions (arrows on the Figure 2) were observed in T1 birds. The lesion observed in the T1 group is consistent with age, as reported by Yegani and Korver (2008). They reported that age is a factor that can affect the gastrointestinal health of poultry and the absence of lesion in the villi histology of birds with *in ovo* supplementation of oyster mushroom extract maybe due to the antioxidant property of oyster mushroom, as well as the presence of linoleic acid in oyster mushroom, which stimulates the biosynthesis of glands and cell membrane. These findings support an earlier report by Subramaniyan *et al.* (2019) that *in ovo* feeding improved tissue representation and prevented lesions in tissues. Similarly, Odutayo *et al.* (2021) reported that *in ovo* administration of amino acids enhanced duodenal histology with high intestinal villi and high crypts in FUNAAB-ALPHA chickens.

CONCLUSION

In ovo administration of oyster mushroom is appropriate for the improvement of intestinal health of broiler chickens with respect to improved jejunal

morphology in the starter phase as well as increased intestinal length and superior duodenal histology in the finisher phase.

ACKNOWLEDGEMENT

All authors appreciate the Centre of Excellence in Agricultural Development and Sustainable Environment of the Federal University of Agriculture, Abeokuta for providing the grant to perform this study.

AUTHOR'S CONTRIBUTIONS

Conceptualization: Daini, O., Sogunle, O.

Methodology: Daini, O., Sogunle, O., Adebambo, A.

Investigation: Daini, O., Sogunle, O., Safiyu, K., Odutayo, O., Irivboje, O.

Data curation: Daini, O., Sogunle, O., Adebambo, A., Safiyu, K.

Writing-original draft preparation: Daini, O.

Writing-review and editing: Daini, O., Sogunle, O., Safiyu, K.

Project administration: Daini, O., Sogunle, O., Adebambo, A.

All authors have read and agreed to the published version of the manuscript.

DATA AVAILABILITY STATEMENT

The data presented in this study are available on request from the corresponding author.

CONFLICT OF INTEREST

The authors declare no conflict of interest.

REFERENCES

- Baurhoo, B., Phillip, L. & Ruiz-Feria, C. A. (2007). Effects of purified lignin and mannan oligosaccharides on intestinal integrity and microbial populations in the ceca and litter of broiler chickens. *Poultry Science*, 86(6), 1070–1078.
- Bhanja, S. K., Mandal, A. B. & Goswami, T. K. (2004). Effect of *in ovo* injection of amino acids on growth, immune response, development of digestive organs and carcass yield of broiler. *Indian Journal of Poultry Science*, 39, 212–218.
- Bohorquez, D. V., Bohorquez, N. E. & Ferket, P. R. (2011). Ultrastructural development of the small intestinal mucosa in the embryo and turkey: A light and electron microscopy study. *Poultry Science*, 90, 842–855.
- Chegini, S., Kiani, A. & Rokni, H. (2018). Alleviation of thermal and overcrowding stress in finishing broilers by dietary propolis supplementation. *Italian Journal of Animal Science*, 17, 377–385.
- Dibner, J. J. & Richards, J. D. (2005). Antibiotics growth promoters in agriculture: History and mode of action. *Poultry Science*, 84, 634–643.
- Elmastas, M., Isildak, O., Turkecul, I. & Temur, N. (2007). Determination of antioxidant activity and antioxidant compounds in wild edible mushrooms. *Journal of Food Composition and Analysis*, 20, 337–345.
- Eyng, C., Murakami, A. E., Duarte, C. R. A. & Santos, T. C. (2014). Effect of dietary supplementation with an ethanolic extract of propolis on broiler intestinal morphology and digestive enzyme activity. *Journal of Animal Physiology and Animal Nutrition*, 98, 393–401.
- Fabio, M. (2008). Basic aspects of *in-ovo* injection in commercial hatcheries. *Hatchery Expertise Online*, Issue No. 20 / September 2008.
- Fazayeli-Rad, A. R., Afzali, N., Farhangfar, H. & Asghari, M. R. (2015). Effect of bee pollen on growth performance, intestinal morphometry and immune status of broiler chicks. *European Poultry Science*, 79, 1–9.
- Giannenas, I., Pappas, I. S., Mavridis, S., Kontopidis, G., Skoufos, J. & Kyriazakis, I. (2010). Performance and antioxidant status of broiler chickens supplemented with dried mushrooms (*Agaricus bisporus*) in their diet. *Poultry Science*, 89(2), 303–311.
- Gilani, S. M. H., Rashid, Z., Galani, S., Ilyas, S., Sahar, S., Zahoor-Ul-Hassan, Al-Ghanim, K., Zehra, S., Azhar, A., Al-Misned, F., Ahmed, Z., Al-Mulham, N. & Mahboob, S. (2021). Growth performance, intestinal histomorphology, gut microflora and ghrelin gene expression analysis of broiler by supplementing natural growth promoters: A nutrigenomics approach. *Saudi Journal of Biological Sciences*, 28(6), 3438–3447.
- Gonzales, E., Kondo, N., Saldanha, S. P. B., Loddy, M., Careghi, C. & Decuypere, D. (2003). Performance and physiological parameters of broiler chickens subjected to fasting on the neonatal period. *Poultry Science*, 82, 1250–1256.
- Google Map. (2019). Federal University of Agriculture. Retrieved from <https://earth.google.com/web/@7.22330744,3.44033719,137.84884575a,1046.69760578d,35y,100.57030218h,44.99999706t,-0r/data=Cm4abBjMciUweDEwM>. Accessed October 2019.
- Guo, F. C., Kwakkel, R. P., Williams, B. A., Li, W. K., Li, H. S., Luo, J. Y., Li, X. P., Wei, Y. X., Yan, Z. T. & Verstegen, M. W. A. (2004). Effects of mushroom and herb polysaccharides, as alternatives for an antibiotic, on growth performance of broilers. *British Poultry Science*, 45, 684–689.
- Hadi, S. M., Ibrahim, K. M. & Yousif, S. I. (2014). Effect of shock and elevated levels of mannitol on callus growth, regeneration and proline accumulation in *Ruta graveolens* cultures. *International Journal of Current Microbiology and Applied Sciences*, 3(11), 479–488.
- Latour, M. A., Peebles, E. D., Boyle, C. R. & Brake, J. D. (2003). The effects of dietary fat on growth performance, carcass composition, and feed efficiency in the broiler chick. *Poultry Science*, 73, 1362–1369.
- Leeson, S. (2008). Predictions for commercial poultry nutrition. *Journal of Applied Poultry Research*, 17, 315–322.
- Machado, A. M. B., Dias, E. S., Santos, E. C. D. & De Freitas, R. T. F. (2007). Exhausted compound of the mushroom *Agaricus blazei* in the diet of broilers. *Revista Brasileira de Zootecnia*, 36, 362–370.
- Noy, Y., Geyra, A. & Sklan, D. (2001). The effects of early feeding on growth and small intestinal development in the post hatch poultry. *Poultry Science*, 80, 912–919.
- Obun, C. O. & Osaguona, P. O. (2013). Influence of post-hatch starvation on broiler chick's productivity.

- IOSR Journal of Agriculture and Veterinary Science*, 3(5), 5–8.
- Odutayo, O. J., Sogunle, O. M., Adeyemi, O. A., Sonibare, A. O. & Safiyu, K. K. (2021). Effect of *in ovo* arginine injection on Gastrointestinal and Haemato-biochemical indicators of FUNAAB-alpha chickens. *Slovak Journal of Animal Science*, 54(3), 113–120.
- Olatoye, I. O. & Ehinwomo, A. A. (2009). Oxytetracycline Residues in Edible tissues of cattle slaughtered in Akure, Nigeria. *Internet Journal of Food Safety*, 11, 62–66.
- Sadler, M. (2003). Nutritional properties of edible fungi. *British Nutritional Found Nutrients Bulletin*, 28, 305–308.
- Salmanzadeh, M. (2012). The effects of *in ovo* injection of glucose on hatchability, hatching weight and subsequent performance of newly-hatched Chicks. *Brazilian Journal of Poultry Science*, 14(2), 71–158.
- Salmanzadeh, M., Ebrahimnezhad, Y., Shahryar, H. A., & Lotfi, A. (2011). The effects of *in ovo* injection of L-threonine in broiler breeder eggs on characters of hatching and growth performance broiler chickens. *European Journal of Experimental Biology*, 1(4), 164–168.
- Shareef, A. M., Jamel, Z. T. & Yonis, K. M. (2009). Detection of antibiotic residues in stored poultry products. *Iraqi Journal of Veterinary Science*, 23(1), 45–48.
- Sklan, D. (2001). Development of the digestive tract of poultry. *Poultry Science*, 57, 415–428.
- Sogunle, O. M., Azeez, N. T., Safiyu, K. K., Irvboje, O. A., Adeyemi, O. A., Wheto, M., Odutayo, O. J. & Uyeno, Y. (2021). Effect of *in ovo* and post-hatch administration of aqueous extract of oyster mushroom on immune response, tibiae morphometry and minerals, and bone marrow histology of broiler chickens. *Archivos de Zootecnia*, 70 (271), 284–290.
- Sogunle, O. M., Daini, O. E., Safiyu, K. K., Odutayo, O. J. & Labinjo, J. (2017). Response of cockerel chickens to oyster mushroom (*Pleurotus ostreatus*) administered in feed. 42nd Annual Conference, Nigerian Society for Animal Production 26–30th March 2017, Landmark University, Omu-Aran. *Animal Welfare Issues and Climate Change*, 636–638.
- Sogunle, O. M., Elangovan, A. V., David, C. G., Ghosh, J. & Awachat, V. B. (2018). Response of broiler chicken to *in ovo* administration of inorganic salts of Zinc, Selenium and Copper or their combination. *Slovak Journal of Animal Science*, 51(1), 8–19.
- Soltani, T., Salarmoini, M., Afsharmanesh, M. & Tasharrofi, S. (2019). The Effects of *in ovo* Injection of Ascorbic Acid on Hatchability, Growth Performance, Intestinal Morphology, and Tibia Breaking Strength in 36 h Post Hatch Fasted Broiler Chickens. *Poultry Science Journal*, 7(1), 43–49.
- Subramaniyan, S. A, Park. J. R, Siddiqui. R. R, Yoo. D. J. & Shim, K. S. (2019). Effect of *in ovo* injection of L-Arginine in different chicken embryonic development stages on post-hatchability, immune response, and Myo-D and Myogenin proteins. *Animal Science Journal*, 9, 357–377.
- Tekeli, A., Kutlu, H. R., Çelik, L. & Doran, F. (2010). Determination of the effects of *Z. officinale* and propolis extracts on intestinal microbiology and histological characteristics in broilers. *International Journal of Poultry Science*, 9, 898–906.
- Uni, Z. & Ferket, P. R. (2004). Methods for early nutrition and their potential. *Worlds Poultry Science Journal*, 60, 101–111.
- Uni, Z., Noy, Y. & Sklan, D. (1999). Post hatch development of small intestinal function in the poult. *Poultry Science*, 78, 215–222.
- Wang, J., Li, S., Wang, Q., Xin, B. & Wang, H. (2007). Trophic Effect of Bee Pollen on Small Intestine in Broiler Chickens. *Journal of Medicinal Food*, 10, 276–280.
- Willemsen, H., Debonne, M., Swennen, Q., Evereaert, N., Careghi, C., Han, H., Bruggeman, V., Tona, K. & Decuypere, E. (2010). Delay in feed access and spread of hatch: Importance of early nutrition. *World's Poultry Science Journal*, 66, 189–199.
- Willis, W. L., Isikhuemhen, O. S. & Ibrahim, S. A. (2007). Performance assessment of broiler chickens given mushroom extract alone or in combination with probiotics. *Poultry Science*, 86, 1856–1860.
- Yang, Y. & Feng, W. S. (1998). Brochures of isolation and extraction of chemical components from herbs. China Chinese Herb Medicine Press, Beijing, China.
- Yegani, M. & Korver, D. (2008). Factors affecting intestinal health in poultry. *Poultry Science*, 87, 2052–2063.
- Yogeswari, R., Murugesan, S. & Jagadeeswaran, A. (2012). Hepatoprotective effect of oyster mushroom (*Pleurotus sajor caju*) in Broilers Fed Aflatoxin. *International Journal of Veterinary Science*, 1(3), 104–107.